

ARTHRAMIDVET[®]

**2.5% Polyacrylamide Hydrogel
(iPAAG)**



**A dynamic intra-articular
bio-scaffold technology for
treating osteoarthritis in canines**

2024 White Paper





ArthramidVet® for Canines White Paper 2024

Copyright© 2024 Contura Vet Limited
Riverside One
Sir John Rogerson's Quay
Dublin 2. Ireland

Authors

Greg McGarrell BSc MBA
Alison K. Howell BVSc MSc MRes PhD MRCVS
Jennifer R. Eden BVSc Cert AVP MRCVS
John D. Reilly BSc (Hons) BVSc PhD MRCVS
Matthew W. Brunke DVM, DACVSMR, CCAT, CCRP
Megan M. Green, DVM

All rights reserved.

No part of this document may be reproduced in any form, by photocopy, photo or xerography, or any other means, or incorporated into any information retrieval system, electronic or mechanical, without the written permission of Contura Vet Limited.



Contents

1	Introduction	3
2	Osteoarthritis in the canine	3
	2.1 Epidemiology	3
	2.2 Pathophysiology	3
3	About 2.5% iPAAG	
	3.1 Manufacturing	5
	3.2 Mechanism of action	6
	3.3 Clinical safety	6
4	Use of 2.5% iPAAG	
	4.1 Equines	7
	4.2 Humans	7
	4.3 Canines	7
5	2.5% iPAAG in Canines - a retrospective case series	8
6	Implementing 2.5% iPAAG injection into practice in Canines	10
	6.1 Case selection	10
	6.2 Case management	10
	6.3 Advised volumes of ArthramidVet® to use in canine joints	10
7	References	11

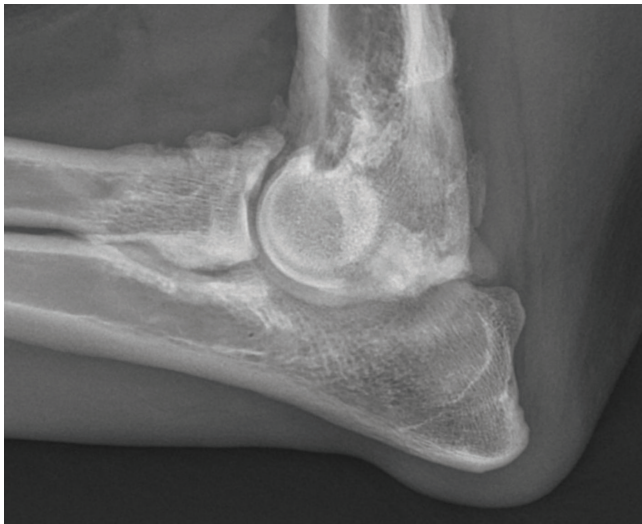
1 | Introduction

Osteoarthritis (OA) is a major clinical and welfare problem in canines, particularly in certain breeds that are pre-disposed to joint disease such as elbow dysplasia, hip dysplasia, and other developmental orthopedic diseases.¹ Current treatments for OA focus on the alleviation of pain, inflammation, and lameness but do not affect the progression of the disease. ArthramidVet® (2.5% injectable polyacrylamide hydrogel - 2.5% iPAAG) is a new approach in the management of OA in canines that is administered via intra-articular injection. It supports cell growth within the joint creating a hyper-cellular subsynovial layer. Rather than simply relieving symptoms, ArthramidVet® offers a versatile, safe, and minimally invasive way to impact the disease progress.

2 | Osteoarthritis in the canine

2.1 Epidemiology

The prevalence of osteoarthritis (OA) in canines is reported at nearly 40%.² While commonly associated with older dogs, research indicates 20% of canines, as young as one year, can suffer from OA.³ OA is often considered to be secondary to wear and tear on the joint, and often occurs secondary to hereditary joint conditions, such as hip and elbow dysplasia and cruciate ligament disease, that are common in dogs of certain breeds.⁴ OA in dogs has similarities to that in people, with the same joints being most commonly affected.⁵



Radiographs courtesy of Dr. Matt Brunke

2.2 Pathophysiology

Resolution of the pain and lameness is a primary concern of owners and often the reason that dogs with osteoarthritis will be presented for veterinary care. There is only a weak correlation between the magnitude of pain and the severity of articular damage observed.²

The synovial joint is comprised of subchondral bone, articular cartilage, synovium, joint capsule, as well as intra-articular and extra-articular ligaments and, in some instances, menisci. A healthy joint is in balance between catabolism and anabolism, with proteoglycan production stimulated by moderate exercise to enable cartilage to withstand compression.⁶⁻⁸ Meanwhile, the interplay between degrading enzymes and their inhibitors allows for adaptive remodeling without the damaging effects of excessive catabolism, that would lead to inflammation.⁹

Previously it was thought that OA was primarily a disease of cartilage; however, it is now recognized that it can start in any of the joint tissues.¹⁰ This can include the synovial membrane, the fibrous joint capsule, synovial fluid, subchondral bone or ligaments, as well as articular cartilage or any combination of the above.

Synovitis is a large contributing factor to the pain of osteoarthritis through joint effusion, swelling, and capsulitis.

In synovial joints, two general types of pain stimuli occur: mechanical caused by changes in the joint such as trauma, and chemical caused by tissue inflammation.⁸ Mechanoreceptors and nociceptors detect these stimuli, then forward it to peripheral nerves, spinal cord, and ultimately to the brain to be processed and perceived. Synovitis results in direct chemical stimulation of nociceptors.⁸ Capsulitis activates mechanoreceptors in the joint capsule, and the mechanoreceptors can become hypersensitized by chemical stimuli released during the inflammation process.⁸

In articular tissues, there are four types of afferent receptors.⁸

Type 1 are low threshold mechanoreceptors with proprioceptive function located in the joint capsule.

Type 2 are low threshold mechanoreceptors activated during motion with dynamic proprioception function and located at the joint capsule/sub-synovial tissue junction.

Type 3 are high threshold mechanoreceptors and nociceptors, activated during physiologic limits and located near bony insertions of intra-articular and peri-articular ligaments.

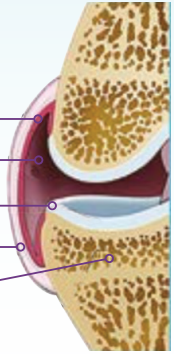
Type 4 are polymodal high threshold nociceptors found as nerve-free endings responding to thermal, chemical, and mechanical stimuli located in the synovial membrane.⁸

Once damage has occurred, cellular metabolism is altered and a cascade of inflammatory mediators released by macrophages, synoviocytes and connective tissue cells result in further damage to tissues.^{9,10} This leads to an imbalance to the normal homeostasis of the joint causing a catabolic state. The joint capsule loses elasticity, resulting in decreased ability to transfer load and increased forces through the joint.^{11,12} Microscopically, there is a loss of proteoglycan caused by enzymatic degradation.⁹ Damaged cartilage initially increases its water content and swells. Loss of chondrocytes results in fibrillation and lessened resistance to shear forces results in further damage.⁹ This can eventually lead to small fragments of cartilage and/or bone occupying the joint space, eliciting a further inflammatory response and perpetuating the cycle.⁹ Repeated loading of bone leads to subchondral bone sclerosis, and osteophytes are also a common occurrence.⁹ These events manifest clinically as a slow, progressive, painful disease with lameness and reduced joint function.

Joint Structure

Normal

1. Synovium
2. Synovial Fluid
3. Cartilage
4. Capsule
5. Subchondral Bone



Osteoarthritis

1. Inflamed Synovium
2. Reduced Viscosity of Synovial Fluid
3. Narrowed Joint Space
4. Osteophyte
5. Fibrillated/Destroyed Cartilage
6. Thickened Subchondral Bone
7. Thickened Capsule

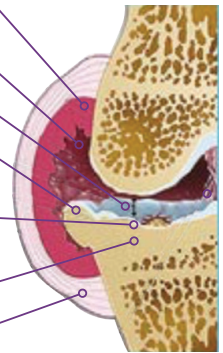


Figure 1. Joint overview: normal stifle vs osteoarthritic lesions.
Image Source: <https://caninearthritis.org/article/arthritis-the-basics/>

Histological Anatomy of a Normal Synovial Membrane

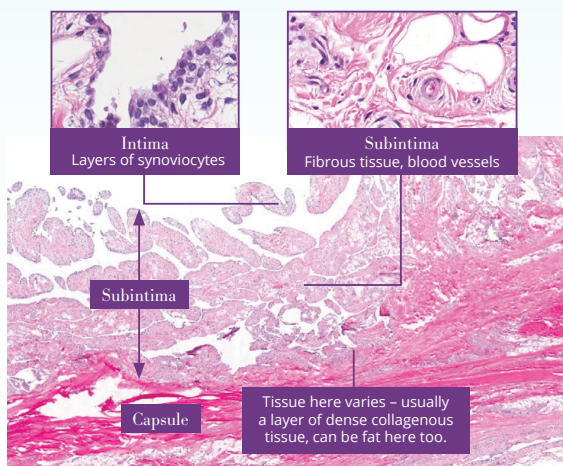
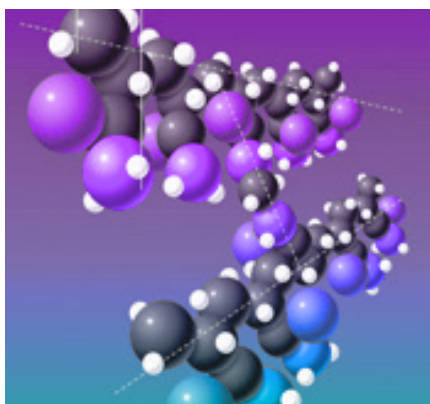


Figure 2. Histological anatomy of the synovial membrane using electron microscopy.
Images captured at 2x, 20x and 40x magnification (Contura Vet image on file).

3 | About 2.5% iPAAG

Polyacrylamide hydrogel (PAAG) is an inert polymer gel with many and varied uses including water purification and soft contact lenses. In 2001, PAAG was first approved and CE-marked in Europe for soft tissue augmentation in humans and has an excellent safety record¹³. It has been used in human carpus for treatment of the human knee, urethrae, tissue, and as a cosmetic filler.^{14–16} ArthramidVet®, a PAAG used for intraarticular use (iPAAG), is made of 97.5% sterile water and 2.5% polyacrylamide.



3D molecular representation of 2.5% PAAG showing cross linking between two molecules of polyacrylamide. Image provided by Contura Vet.

ArthramidVet® is formulated for intra-articular injection. Its excellent biocompatibility has been demonstrated in mice, rats, rabbits, goats, pigs, horses and humans.^{11,14–17} Furthermore, it is non-absorbable, non-degradable, non-pyrogenic and neuro-innocuous. These properties enable it to have a long-lasting augmentation effect.¹⁵

Its first use in veterinary patients was as a treatment for OA in racing and sports horses. More recently, it has been used for OA in human and canine patients.

3.1 Manufacturing

ArthramidVet® is produced by a patented technology called In-line Cross-Linking Technology (ILX Technology), which forces water molecules between the cross-linked polymers of polyacrylamide (CAS No. 9003-05-8), providing the gel with exceptional molecular stability. It consists of polyacrylamide polymers that are cross-linked in a stable three-dimensional network, which is hydrophilic and gives it viscoelastic properties. Large amounts of molecular water remain lightly bound within the structure and constantly interchange with surrounding tissues, supporting cell growth and integration.¹⁵



Machines (pictured above and below) used in the Automated Line of Production of Hydrogels. Images provided by Contura Vet.



3.2 Mechanism of action

Historical studies have shown 2.5% iPAAG begins to integrate into the synovium as synovial cells proliferate and invade into the gel 10 to 14 days after injection into rabbit and horse joints.¹⁸ By day 90 in rabbit joints and day 30 in horse joints, the gel forms a thick sub-synovial layer traversed by new blood vessels and thin strands of connective tissue covered by a hypercellular synovial lining. This histological appearance persists for up to two years post-injection in horse joints.¹⁸

Investigations using a randomized controlled trial of 2.5% iPAAG in an experimental model of OA in the goat stifle supported these findings.^{11,19} These combined effects on cartilage and joint capsule help to protect the underlying tissues. It is thought that this leads to a reduction in mechano- and noci-receptor activation in the joint capsule and, in addition, the new hypercellular synovial layer improves the nature of the synovial fluid.¹¹ Production of pro-inflammatory cytokines is then reduced, slowing the damaging progression of OA and helping to restore the joint to healthier function. MRI performed at three, four, five and seven months after treatment showed a reduction of OA lesions in cartilage, followed by stabilization.¹¹ Histopathology at seven months showed the 2.5% iPAAG was integrated into the synovial membrane, with new vessel growth and an increase in collagen and synovial cells. Use of stress measurements on pieces of joint capsule at post-mortem examination demonstrated that the treated joint capsules had greater elasticity than the untreated.¹¹ Joint capsule stiffness is recognized to be a major cause of pain in OA, so this finding suggests an important mechanism of action in OA is the ability to reduce joint capsule stiffness and increase load transfer capacity.¹¹

These combined effects on cartilage and joint capsule help to protect the underlying tissues. It is thought that this leads to a reduction in mechano- and noci-receptor activation in the joint capsule and, in addition, the new hypercellular synovial layer improves the nature of the synovial fluid.¹¹ Production of pro-inflammatory cytokines is then reduced, slowing the damaging progression of OA and helping to restore the joint to healthier function.

3.3 Clinical safety

The polymers of acrylamide used to manufacture 2.5% iPAAG are stable and inert, making them non-toxic.²¹ PAAG has been shown not to degrade or migrate for up to eight years in human tissue.¹⁴ Localized mild to moderate inflammation is rarely reported, with one study reporting 55 adverse events from 2.5% iPAAG use as a facial filler in 40,000 patients.²² In vivo studies that assessed the effect of 2.5% iPAAG on nerves in treated joints found no visible negative effects.¹¹

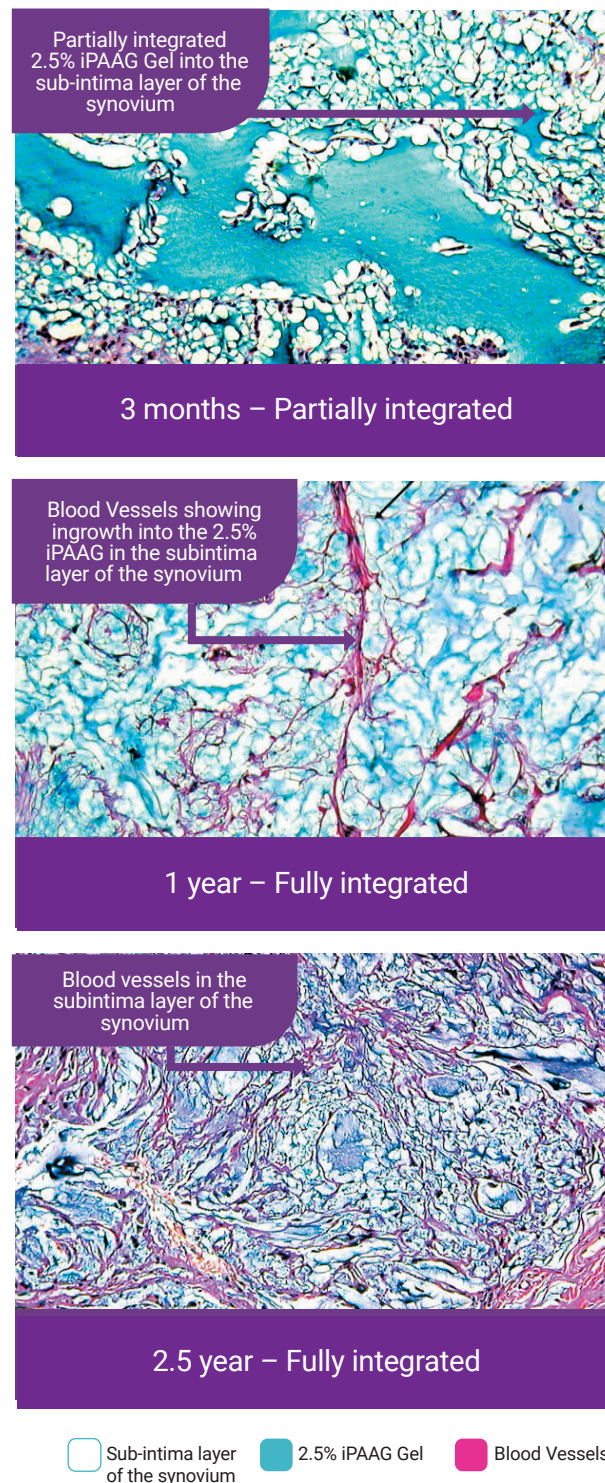


Figure 3. Contura Vet histology images on file. At 3 months the proliferated synovial lining is intact on top of a layer of PAAG. Later a fine fibrous network with blood vessels is present inside the gel. Synovial lining is intact on top of layer of 2.5% iPAAG.¹⁸

4 | Use of 2.5% iPAAG

4.1 Equines

2.5% iPAAG (ArthramidVet®) is now well-established as a treatment for OA in performance horses in the United States and worldwide where it has a marketing authorization for veterinary use. Clinical studies describe an improvement in lameness in approximately 75% of horses from 4 weeks after treatment, with the proportion of sound horses plateauing at between six and 12 weeks, and the benefits lasting up to two years.^{23–26} Excellent results have been seen in horses treated early,^{23–25} and also in those in later stage OA, including cases refractory to commonly used treatments.^{23,25,27}



4.2 Humans

The equivalent product, Arthrosamid®, has been introduced for use in OA in people and received the European Marketing Approval since April 2021.²⁸ Significant improvements in pain, stiffness and function lasting up to 36 months are reported,²⁹ with no serious side effects.²⁸



4.3 Canines

ArthramidVet® is a relatively novel OA intervention for dogs. In the United States, ArthramidVet® is Food and Drug Administration (FDA) permitted for use under its classification as a 'Veterinary Medical Device' and is available to any licensed veterinarian. In the United Kingdom, ArthramidVet® has been legitimately used as an 'off-licence' product, under the veterinary cascade system, since 2017.³⁰

With U.S.-based distribution, any licensed vet has access to the product in the United States, but in other countries, licensed veterinary surgeons must seek permission from their own veterinary authorities to import ArthramidVet® for clinical use. Contura Vet support staff can help with this process.



5 | 2.5% iPAAG in Canines - a retrospective case series

A database exists of 166 dogs with joint disease from three veterinary practices in the United Kingdom, for which ArthramidVet® was used (Contura Vet internal data). Questionnaires and historical clinical records were used to collect data on outcomes as perceived by owners and veterinary surgeons. Elbows, hips and stifles were the most commonly treated joints in these dogs, with osteoarthritis, elbow dysplasia, hip dysplasia, and lameness most often recorded as the reason for treatment. The majority of the dogs were receiving non-steroidal anti-inflammatories or other systemic analgesics at the time of intra-articular administration of ArthramidVet®.

- A reduction in lameness post-ArthramidVet® treatment was seen from 1 month and was maintained for at least six months in 71.7% of dogs treated. (*1 Figure 4)
- The data showed reduced or stopped systemic analgesics in case management in 67.4% of treated dogs. (*2 Table 1)
- Up to 72.8% of surveyed owners responded 'extremely pleased' or 'pleased' with the outcome of ArthramidVet® injection. (*3 Table 2)
- Up to 86.4% of owners saw improvements in the quality of life in their dogs after ArthramidVet® injection. (*4 Table 2)
- Up to 81.9% of owners responded 'extremely likely' or 'likely' when asked if they would recommend ArthramidVet® injection to other dog owners. (*5 Table 2)

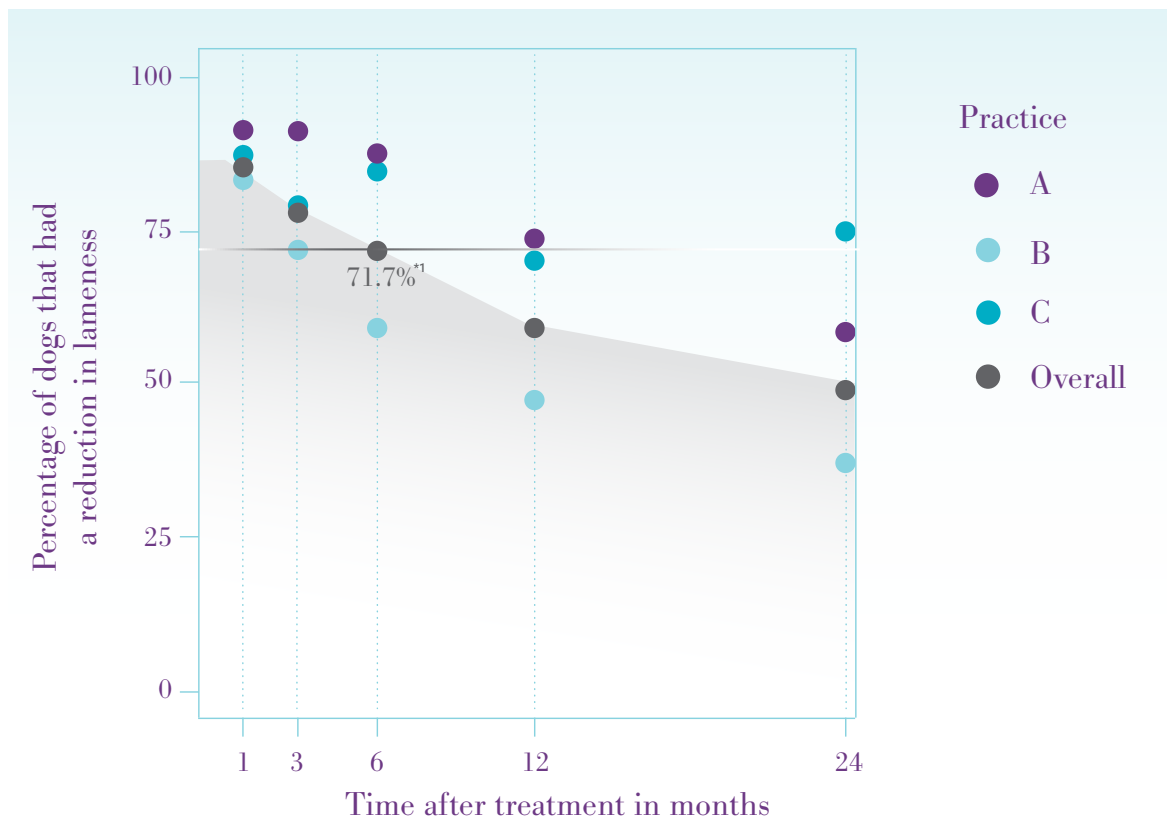


Figure 4: The percentage of dogs for which follow up was available that achieved sufficient improvement in clinical condition to meet the expectation of the treating veterinary surgeon, at various time points after treatment with ArthramidVet®. Practices A and C were first opinion practices while B was a referral centre. (Contura Vet data on file).

Table 1. Numbers of dogs from each practice that were able to stop or reduce systemic analgesics after ArthramidVet® injection.

	Practice A	Practice B	Practice C	Total
Yes, for less than 6 months	0	20 (23.8%)	0	^{*2} 20 (15.5%)
Yes, for more than 6 months	17 (58.6%)	48 (57.1%)	0	^{*2} 65 (50.3%)
Yes, no time mentioned	0	0	2 (12.5%)	^{*2} 2 (1.5%)
No	12 (41.4%)	16 (19.0%)	14 (87.5%)	42 (32.6%)
Total	29	84	16	129
Don't know	4	2	1	7
Not applicable as not on any medication	2	22	6	30

^{*2} 20+^{*2} 65+^{*2} 2 = 87 cases out of 129 cases (67.4%) were able to reduce or stop systemic analgesics in case management.

Table 2. Owner responses to questionnaires after intra-articular ArthramidVet® was given to their dog.

Responses received		Primary Care Owners (Practice A and C responses)
		38/58 (65.5%)
Question	Answer	
Were you pleased with the outcome of the joint injection(s)?	I was extremely pleased	^{*3} 17 (44.7%)
	I was pleased	^{*3} 11 (28.9%)
	I saw no change	6 (15.8%)
	I was disappointed	3 (7.9%)
	I was extremely disappointed	2 (5.2%)
Overall, how do you think the quality of life of your dog was affected by the joint injection(s)?	An increase in quality of life	^{*4} 30 (78.9%)
	No change	6 (15.8%)
	A decrease in quality of life	2 (5.3%)
How likely would you be to recommend this injection to other dog owners?	Extremely likely	^{*5} 17 (44.7%)
	Likely	^{*5} 12 (31.6%)
	Neither recommend nor not recommend	4 (10.5%)
	Unlikely	5 (13.2%)
	Extremely unlikely	0

^{*3} For Practice A 72.8% of owners were extremely pleased or pleased with the outcome. For Practice C 68.8% of owners were extremely pleased or pleased with the outcome.

^{*4} For Practice A, 86.4% of owners saw improvements in quality of life. For Practice C 68.8% of owners saw improvement in quality of life.

^{*4} Of 38 responses, ^{*3}19 + ^{*3}11 = 30 (78.9%) reported an increase in quality of life.

^{*5} For Practice A, 81.9% of owners were extremely likely or likely to recommend ArthramidVet® injection to other dog owners. For Practice C 68.8% of owners were extremely likely or likely to recommend ArthramidVet® injection to other dog owners.

6 | Implementing 2.5% iPAAG injection into practice in Canines

6.1 Case selection

Osteoarthritis can have multiple causes; therefore it is vital to determine the cause before initiating any intervention. Cases suitable for ArthramidVet® treatment are those in which lameness can be localized to a synovial joint. ArthramidVet® may be used for both early- and late-stage joint disease, including in cases refractory to other treatments. It is not indicated for use in cases of articular fractures but can be considered once the fracture has healed. There is no requirement to see evidence of OA on radiographs, for example, in early cases of OA (synovitis), but radiography would be expected in most cases following the ruling out of septic, neoplastic, and other causes of lameness to ensure an accurate diagnosis as part of a normal work up according to the vet's professional discretion.

6.2 Case management

Following injection of ArthramidVet®, animals should be rested for 48 hours. After this time, the animal can return to low-impact restricted exercise, slowly increasing exercise in a controlled program over the next two to four weeks. Animals typically show a gradual reduction in lameness after injection. By four to six weeks no further improvement is expected and re-examination at four to six weeks is therefore indicated. It is important for owners to understand this time lag in response, as this contrasts with conventional therapies. Repeat doses may be given depending on response. In some cases of nil or partial response, an additional injection may be indicated after four to six weeks.

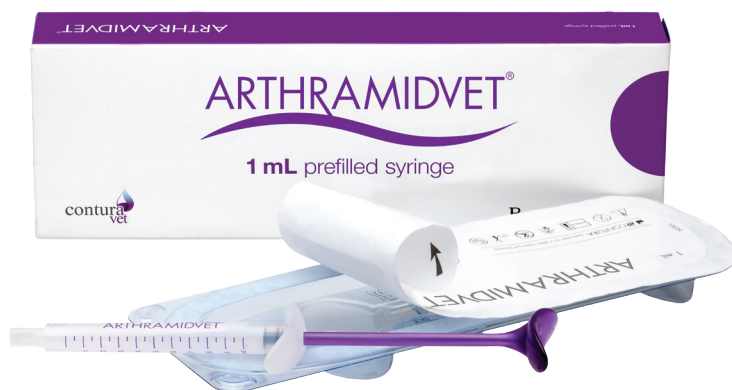Concurrent use of systemic NSAIDs may be useful and carries no contra-indications; however, ArthramidVet® should not be used concurrently with intra-articular steroids, extracorporeal shockwave therapy, or other modalities. These modalities can be used prior to injection of ArthramidVet®, but are not recommended to use for at least six weeks after injection, to prevent interference with synovial integration.

6.3 Advised volumes of ArthramidVet® to use in canine joints

The following volume recommendations have been made, based on observed clinical responses to administration:

CANINE	
Joint	Dose
Large: Shoulder, elbow, hip and stifle	0.5 - 1.0 mL
Medium: Carpus and Tarsus	0.25 - 1.0 mL
Small: Inter-phalangeal joint	0.01 - 0.1 mL

A single injection of the above-advised volume is considered adequate administration to achieve the effect. Concurrent treatment of multiple joints can be performed.



7 | References

1. Wright A, Amodie AM, Cernicchiaro N, et al. Identification of canine osteoarthritis using an owner reported questionnaire and treatment monitoring using functional mobility tests. *J Small Anim Pract.* 2022;63(8):609-618.
2. Enomoto, M., de Castro, N., Hash, J., Thomson, A., Nakanishi-Hester, A., Perry, E., Aker, S., Haupt, E., Opperman, L., Roe, S., Cole, T., Thompson, N. A., Innes, J. F., & Lascelles, B. D. X. (2024). Prevalence of radiographic appendicular osteoarthritis and associated clinical signs in young dogs. *Scientific reports*, 14(1), 2827. <https://doi.org/10.1038/s41598-024-52324-9>.
3. Johnston, S. A. Osteoarthritis – joint anatomy, physiology, and pathobiology. *Veterinary Clinics of North America: Small Animal Practice* 27, 699-724 (1997).
4. Pettitt, R. A. & German, A. J. Investigation and management of canine osteoarthritis. In *Pract.* 38, 1–8 (2016).
5. Meeson, R. L., Todhunter, R. J., Blunn, G., Nuki, G. & Pitsillides, A. A. Spontaneous dog osteoarthritis – a One Medicine vision. *Nature Reviews Rheumatology* vol.15 273–287 (2019).
6. Palmer, S. & Bertone, A. Joint biomechanics in the pathogenesis of traumatic arthritis. in *Joint disease in the Horse* (eds. McIlwraith, C. W. & Trotter, G. W.) 104–119 (W.B. Saunders, 1996).
7. Lohmander, S. Proteoglycans of joint cartilage. Structure, function, turnover and role as markers of joint disease. *Bailliere's Clinical Rheumatology* vol. 2 (Baillière Tindall, 1988).
8. Van Weeren, P. R. & de Grauw, J. C. Pain in osteoarthritis. *Vet. Clin. North Am. - Equine Pract.* 3, 619–42 (2010).
9. Kidd, J. A., Fuller, C. & Barr, A. R. S. Osteoarthritis in the horse. *Equine Vet. Educ.* 13, 160–168 (2010).
10. Dean, D. D., Azzo, W., Martel-Pelletier, J., Pelletier, J. P. & Woessner, J. F. J. Levels of metalloproteases and tissue inhibitor of metalloproteases in human osteoarthritic cartilage - PubMed. *J. Rheumatol.* 14 Spec No, 43–44 (1987).
11. Tnibar, A., Persson, A.-B. & Jensen, H. . Mechanisms of Action of an Intraarticular 2.5% Polyacrylamide Hydrogel (Arthramid Vet) in a Goat Model of Osteoarthritis: Preliminary Observations. *SM J. Biomed. Eng.* 3, 1022 (2017).
12. Hall, M. C., Doherty, S., Zhang, W. & Doherty, M. Knee joint stiffness and its relationship with severity of radiographic osteoarthritis, pain and self-reported stiffness. *Osteoarthr. Cartil.* 22, S92 (2014).
13. Pallua, N., & Wolter, T. P. (2010). A 5-year assessment of safety and aesthetic results after facial soft-tissue augmentation with polyacrylamide hydrogel (Aquamid): a prospective multicenter study of 251 patients. *Plastic and reconstructive surgery*, 125(6), 1797–1804. <https://doi.org/10.1097/PRS.0b013e3181d18158>
14. Christensen, L. H., Breiting, V. B., Aasted, A., Jørgensen, A. & Kebuladze, I. Long-Term Effects of Polyacrylamide Hydrogel on Human Breast Tissue. *Plast. Reconstr. Surg.* 111, 1883–1890 (2003).
15. Christensen, L. H., Nielsen, J. B., Mouritsen, L., Sørensen, M. & Lose, G. Tissue integration of polyacrylamide hydrogel: An experimental study of periurethral, perivesical, and mammary gland tissue in the pig. *Dermatologic Surg.* 34, (2008).
16. Zarini, E. et al. Biocompatibility and tissue interactions of a new filler material for medical use. *Plast. Reconstr. Surg.* 114, 934–942 (2004).
17. Fernández-Cossío, S. & Castaño-Oreja, M. T. Biocompatibility of two novel dermal fillers: Histological evaluation of implants of a hyaluronic acid filler and a polyacrylamide filler. *Plast. Reconstr. Surg.* 117, 1789–1796 (2006).
18. Christensen, L. et al. Synovial incorporation of polyacrylamide hydrogel after injection into normal and osteoarthritic animal joints. *Osteoarthr. Cartil.* 24, 1999–2002 (2016).
19. Tnibar, A. et al. Evaluation of a polyacrylamide hydrogel in the treatment of induced osteoarthritis in a goat model: a randomized controlled pilot study. *Osteoarthr. Cartil.* 22, S477 (2014).

20. Smith, E. A. & Oehme, F. W. Acrylamide and Polyacrylamide: A Review of Production, Use, Environmental Fate and Neurotoxicity. *Rev. Environ. Health* 9, 215–228 (1991).
21. Christensen, L., Breiting, V., Vuust, J. & Hogdall, E. Adverse reactions following injection with a permanent facial filler polyacrylamide hydrogel (Aquamid): Causes and treatment. *Eur. J. Plast. Surg.* 28, 464–471 (2006).
22. Bathe, A. P., Mercedes Read, R. & Briggs, C. Intraarticular polyacrylamide hydrogel for the treatment of 20 horses with non-responsive osteoarthritis of the interphalangeal joints: a prospective study. in *Veterinary Orthopedic Society 43rd Annual Conference* 5 (2016).
23. Janssen, I., Koene, M. & Lischer, C. Intraarticular application of polyacrylamide hydrogel as a treatment of osteoarthritis in the distal interphalangeal joint: case series with 12 horses. *Pferdeheilkunde* 28, 650–656 (2012).
24. Tnibar, A. et al. An international multi-centre prospective study on the efficacy of an intraarticular polyacrylamide hydrogel in horses with osteoarthritis: A 24 months follow-up. *Acta Vet. Scand.* 57, (2015).
25. de Clifford, L. T., Lowe, J. N., McKellar, C. D., McGowan, C. & David, F. A double-blinded positive control study comparing the relative efficacy of 2.5% polyacrylamide hydrogel (PAAG) against triamcinolone acetonide (TA) and sodium hyaluronate (HA) in the management of middle carpal joint lameness in racing Thoroughbreds. *J. Equine Vet. Sci.* Volume 107 (2021).
26. de Clifford, L. T., Lowe, J. N., McKellar, C. D., Bolwell, C. & David, F. Use of a 2.5% Cross-Linked Polyacrylamide Hydrogel in the Management of Joint Lameness in a Population of Flat Racing Thoroughbreds: A Pilot Study. *J. Equine Vet. Sci.* 77, 57–62 (2019).
27. Overgaard, A., Bliddal, H. & Henriksen, M. Clinical Orthopedics Safety of Intra-Articular Polyacrylamide Hydrogel for the Treatment of Knee Osteoarthritis Symptoms : A Retrospective Case Series. *Clin. Orthop. Adv. Res. J.* 2019, 1–6 (2019).
28. Henriksen, M., et al. 3 Year Results From a Prospective Study of Polyacrylamide Hydrogel for Knee Osteoarthritis. Poster 483 presented at OARSI 2023 (2023).
29. Zarini E, Supino R, Pratesi G, Laccabue D, Tortoreto M, Scanziani E, Ghisleni G, Paltrinieri S, Tunesi G, Nava M. Biocompatibility and tissue interactions of a new filler material for medical use. *Plast Reconstr Surg.* 2004 Sep 15;114(4):934-42. doi: 10.1097/01. (2004).
30. Veterinary Medicines Directorate. The cascade: prescribing unauthorized medicines. gov.uk. <https://www.gov.uk/guidance/the-cascade-prescribing-unauthorised-medicines> (2021).



www.arthramid.com