

ARTHRAMIDVET[®]



2.5% iPAAG
Hydrogel

2019 WHITE PAPER

ArthramidVet[®] 2.5% PAAG

Dynamic tissue scaffold for the treatment of joint lameness in horses

ArthramidVet® White Paper 2019

Copyright © 2018, Innovative Medical Solutions Limited,
32 Hill Road, Cambridge, New Zealand

Authors

J.N. Lowe MBA, BVSc, Cert EP.

L. T. de Clifford BVSc Cert AVP PGDipVPS MVSc

N. Sommerville BVSc, MPhil

All rights reserved.

No part of this document may be reproduced in any form,
by photocopy, photo or xerography, or any other means,
or incorporated into any information retrieval system,
electronic or mechanical, without the written permission of
Innovative Medical Solutions limited.

All enquiries should be emailed to Sales@imsvet.com

**The ARTHRAMIDVET® trade mark is used by permission
of Contura Vet Limited**

Contents

CHAPTER 1

Treatment of Joint Lameness & Osteoarthritis in Horses **3**

Introduction 3

Conventional Therapies for Osteoarthritis (OA) 3

CHAPTER 2

Pathophysiology of Osteoarthritis **5**

Introduction 5

Histological Anatomy 5

Inflammation and Synovitis 6

Pain and Synovitis 7

CHAPTER 3

Chemistry and Manufacturing **9**

Chemistry 9

Manufacturing 9

CHAPTER 4

History of its use in Clinical Studies **10**

Clinical Efficacy 10

Prospective Double-Blinded Positive Control Study 11

Histological Studies 12

CHAPTER 5

Mechanism of Action **13**

Introduction 13

2.5% PAAG - A Novel Treatment 13

Mechanism of Action 2.5% PAAG 14

Conclusion 15

CHAPTER 6

Clinical Safety **16**

Safety Studies 16

In Vitro 16

In Vivo 17

Synoviocentesis Studies 17

Conclusion 17

CHAPTER 7

Putting it into Practice **18**

Case Selection 18

Case Management 18

Dosages 19

Key Points 19

In Australia:

Registered under the APVMA No. 86728/0420.
Registered to and distributed by IMS Vet Pty Ltd.

+61 (1800) 931 812
sales@imsvet.com
www.arthramid.com.au

In New Zealand:

Registered pursuant to the ACVM Act 1997, No. A11596.
Registered to and distributed by Innovative Medical Solutions Ltd.

+64 (07) 245 1645
sales@imsvet.com
www.arthramid.co.nz

ArthramidVet® 2.5% PAAG

TREATMENT OF JOINT LAMENESS AND OSTEOARTHRITIS IN HORSES

Introduction

Osteoarthritis (OA) is cited as the most important musculoskeletal disorder in both humans and horses.^{1,2} Clinically, it is associated with lameness and dysfunction of the affected joint, and approximately 60% of all equine lameness is due to OA.^{3,4} Significant economic loss to the equine industry occurs as a result and coupled with welfare concerns, motivates ongoing research into innovative treatments.^{5,6,7} The rapid resolution of lameness by a reduction in pain is paramount, but treatments ideally, should also serve to arrest or slow the progression of the disease.⁸

The use of an intra-articular 2.5% cross-linked polyacrylamide (2.5% PAAG- ArthramidVet®, Contura Vet, Denmark) to treat OA is novel. 2.5% PAAG is integrated into the synovial membrane through a combination of vessel in-growth and molecular water exchange and persists long term in the joint.⁹ This significantly improves joint lameness caused by early and late stages of OA, with trials showing over 75% of cases becoming lame free¹⁰ and for up to 24 months. Its use in racing Thoroughbreds is also confirmed where it is shown to be both superior to and longer lasting than conventional therapies.¹¹

The rapid resolution of lameness by a reduction in pain is paramount, but treatments ideally, should also serve to arrest or slow the progression of the disease.⁸



Conventional Therapies for Osteoarthritis (OA)

Osteoarthritis (OA) is treated symptomatically in the horse.¹² Current conventional therapies include non-steroidal anti-inflammatory drugs (NSAIDs), polysulphated glycosaminoglycans (PSGAGs), corticosteroids, glucosamine, hyaluronic acid and a combination of the above, along with biotechnological substances such as gene therapy, recombinant or autologous growth factors (platelet-rich plasma and interleukin-1 receptor antagonist) and stem cells (allogeneic and autologous chondrocyte transplantation).¹³

The challenge is to develop therapeutic options that both reduce pain and are disease modifying. This would reduce the progression of the deleterious effects OA has on the articular cartilage and surrounding joint structures.

A recent study also showed a positive association between musculoskeletal injury (MSI) rates in Thoroughbred racehorses and local corticosteroid injection.¹⁵ The International Federation of Horse Racing Authorities acknowledged this study and through its welfare committee recommended a 14-day stand-down period as a result.

Intra-articular (IA) corticosteroid administration is one of the most commonly used treatments.¹⁴ Concerns for its ongoing use include steroid-induced deterioration of articular tissues, known as “steroid arthropathy.” The overuse of a treated joint can also result in accelerated cartilage degeneration.² These primary concerns are compounded by additional reports of the adverse effects corticosteroids have on chondrocyte metabolism.⁸ A recent study also showed a positive association between musculoskeletal injury (MSI) rates in Thoroughbred racehorses and local corticosteroid injection.¹⁵ The International Federation of Horse Racing Authorities acknowledged this study and

through its welfare committee recommended a 14-day stand-down period as a result.

IA corticosteroids are commonly combined with hyaluronic acid (HA). There is the perception that the HA might be protective against any deleterious effects of corticosteroids.¹⁶ Studies, however, reveal little or no improvement of OA scores and show little effect against the induced cartilage matrix proteoglycan catabolism in cartilage explants (caused by Methylprednisolone acetate (MPA) in particular).¹⁶

The ideal therapeutic agent for a horse suffering from OA is an agent that alleviates the symptoms of lameness while also providing a positive effect on the articular components resulting in stabilisation or even repair of the pathologic processes occurring in the affected joint.

Mesenchymal Stem Cells (MSCs) have been used for the treatment of tendonitis, arthritis and intra-articular soft tissue injury in horses, as well as for cartilaginous disease. Historically however, several factors have hindered the use of MSCs such as cell source, propagation techniques, and the effects of transportation on cell viability. Furthermore, it is unknown whether MSCs applied directly to an environment full of pro-inflammatory and catabolic substances function successfully or die.¹²

Even so, the use of autologous bone marrow derived concentrate, produced patient-side for the treatment of early partial cranial cruciate ligament and meniscal tears, has been found to provide potential for clinical use.¹⁷ More recently, chondrogenic induced mesenchymal stem cells (ciMSCs) have been shown to offer an alternative to autologous therapy¹⁸, with a study showing that after ciMSCs application in an OA model, treated horses were less lame, and with reduced joint effusion and improved synovial fluid quality compared to saline controls. Nevertheless, another study of 24 horses with induced carpal OA treated with MSCs showed an increase in concentration of PGE2 and TNF-alpha in the synovial fluid.¹⁹ MSCs were not, therefore, recommended for the treatment of OA.

Notwithstanding, whilst the use of MSCs, BMAC or ciMSCs may have been shown in some studies to aid in the treatment of OA,^{17,18} their exact mechanism of action within the OA environment is still poorly understood. MSCs have been shown to produce IL-1Ra post administration into a joint and inhibit inflammation,²⁰ and this mechanism possibly supports findings in those studies where positive outcomes following MSCs treatment in the OA model or OA patient are seen. But whilst inhibiting inflammatory mediators attenuates the disease, further work is required to determine if the use of MSCs are disease modifying in the long-term.

The ideal therapeutic agent for a horse suffering from OA is an agent that alleviates the symptoms of lameness while also providing a positive effect on the articular components resulting in stabilisation or even repair of the pathologic processes occurring in the affected joint.

The era of OA management is shifting towards new therapeutic concepts.¹²



ArthramidVet® 2.5% PAAG

PATHOPHYSIOLOGY OF OSTEOARTHRITIS

Introduction

The two primary functions of a synovial joint are to enable efficient movement and to transfer load.^{5, 21} All of the tissues comprising the synovial joint can be affected by injury, including the subchondral bone, articular cartilage, synovium, and joint capsule as well as intra-articular and extra-articular ligaments and, if present, meniscus.^{22, 23, 24, 25}

It is now well recognised that the OA disease process starts with disease in the synovial membrane, fibrous joint capsule, subchondral bone, or ligaments, as well as articular cartilage or any combination of all of the above.²⁹

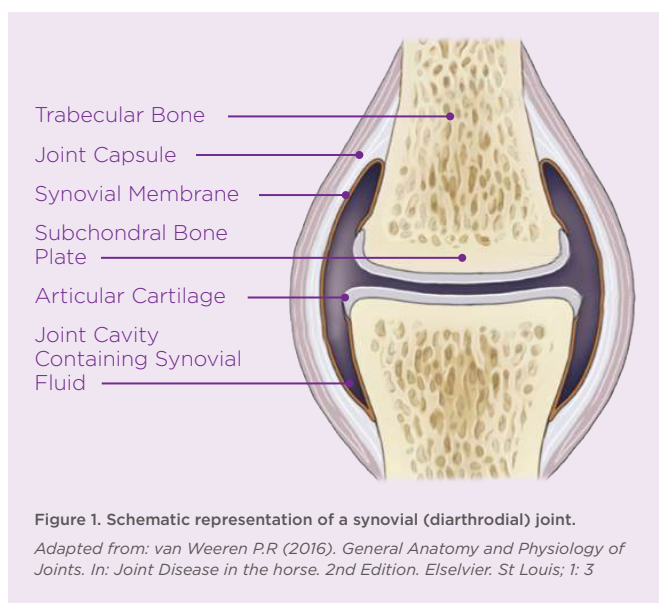


Figure 1. Schematic representation of a synovial (diarthrodial) joint.

Adapted from: van Weeren P.R (2016). *General Anatomy and Physiology of Joints. In: Joint Disease in the horse. 2nd Edition. Elsevier. St Louis; 1: 3*

Equine (OA) is a group of disorders characterised by a common end stage: the progressive deterioration of the articular cartilage accompanied by changes in the bone and soft tissues of the joint.²⁶ Although OA can be classified as a non-inflammatory disease, there are multiple studies indicating that synovitis is an essential component in its pathogenesis,^{2, 5, 27, 28} with it almost always being present in OA cases.²

Indeed, it is now well recognised that the OA disease process starts with disease in the synovial membrane, fibrous joint capsule, subchondral bone, or ligaments, as well as articular cartilage or any combination of all of the above.²⁹

Histological Anatomy

Synovial joints are considered complex organs in which all constituent tissues (articular cartilage, subchondral bone, and synovial membrane) interact with each other, both directly and via the synovial fluid, in health and disease.³⁰

The synovial intima is lined by a diverse population of synoviocytes, classified according to their ultrastructure.³¹ Type A cells are macrophages, implicated in phagocytosis of fluid, foreign material, and microbes. Type B cells are fibroblasts; locally derived cells that produce structural components including collagen. Type C cells appear to be an intermediate between type A and B forms. Beneath this synoviocyte cellular layer is the subintima, comprised of fibrous and adipose tissue, with blood vessels and small numbers of inflammatory cells. The deepest layer is loose connective tissue that allows the membrane to move freely. Ligaments, tendons, or capsular fibrous tissue are located outside of that.

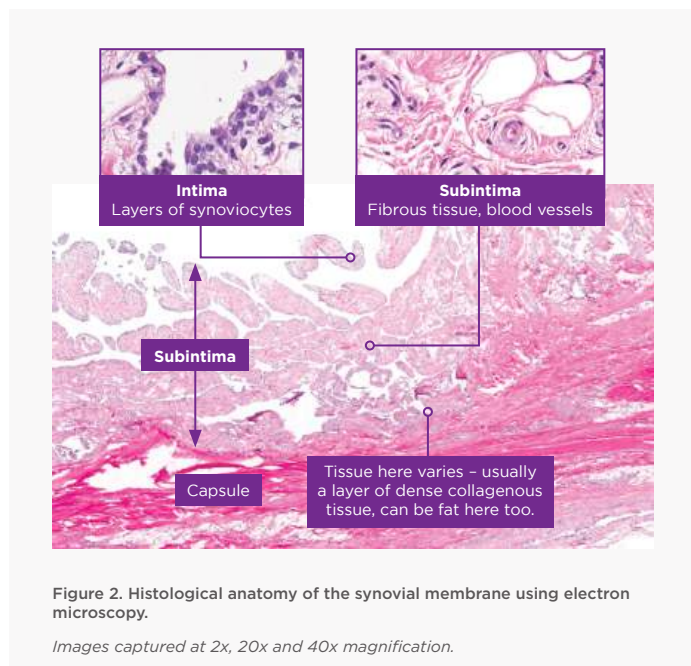
The synovial membrane becomes a source of proinflammatory and catabolic products, which contribute to articular matrix degradation

Two important molecules produced by synovial lining cells are lubricin and hyaluronic acid which help to protect and maintain the integrity of articular cartilage surfaces in synovial joints.³² Together, these two molecules reduce friction by providing boundary lubrication at the articular surface. As part of the OA complex, elastoviscosity of the synovial fluid is abnormally low.³³

The clinical syndrome of OA is quite variable, with differences in affected joint patterns, risk factors, rates of progression, and severity of symptoms.³²

Previous studies have shown that alteration of the friction-lowering function of synovial fluid may contribute to the deterioration of articular cartilage in joint disease and, after joint injury in the horse.³⁴ Furthermore, the synovial membrane becomes a source of proinflammatory and catabolic products, which contribute to articular matrix degradation.

Although structural joint damage in OA is a constant feature, the clinical syndrome of OA is quite variable, with differences in affected joint patterns, risk factors, rates of progression, and severity of symptoms.³² It is recognised that early structural changes seen associated with OA may remain asymptomatic for many years.³⁰ This again highlights the opportunity for a novel therapeutic agent that assists in disease modification and allows for preventative and therapeutic strategies.



Inflammation and Synovitis

Multiple pathologic states develop after either single or repetitive traumas that are the initial “take-off” for progression towards OA. These can include traumatic injury, synovitis, capsulitis, sprain, intra-articular fractures, and meniscal tears.^{4, 5} All of which lead to a common final end-stage of joint failure.^{5, 23, 35, 36, 37} Inflammation is most intense in acute synovitis and is one of the initial changes to occur in the development of OA.^{24, 25, 38} Furthermore, the presence of synovitis in OA is associated with more severe pain, and joint dysfunction.³⁹ This is shown to correlate with symptom severity, the rate of cartilage degeneration, and osteophytosis.

In athletic and young horses, synovitis and capsulitis are changes that occur early on and are assumed to be associated with repetitive trauma.^{4, 5} This aetiology originates most often from overuse and conformational problems predisposing the horse to inappropriate biomechanical forces on the articular cartilage.⁵

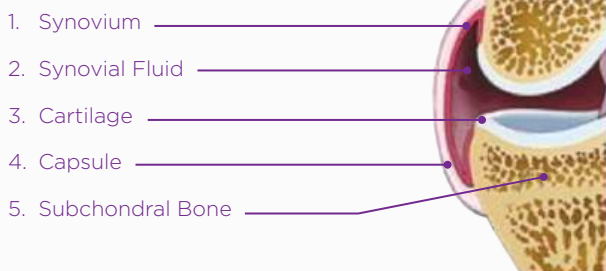
THERE ARE THREE HYPOTHETICALLY PATHOGENIC PATHWAYS FOR OA.

1. The most commonly accepted theory is that cartilage gets damaged due to different mechanical forces, which generates injury to cells and matrix, and to metabolic alterations of chondrocytes, which will start a cascade of a release of proteolytic enzymes resulting in cartilage fibrillation and breakdown of the proteoglycan network. Cartilage is relatively susceptible to repetitive trauma compared to its ability to resist shear forces.⁴⁰ Therefore, repeated trauma is assumed to be one of the most common factors of OA in horses.³¹
2. A second pathway describes the cartilage as being principally defective, with abnormal biomechanical properties that will fail under normal loading.^{5, 31}
3. The third pathway involves physical changes in the subchondral bone.³¹ The thin articular cartilage cannot work as an effective shock absorber. Therefore, the subchondral bone protects the cartilage from damage by providing a flexible surface to absorb forces placed on the joint.²³

In athletic and young horses, synovitis and capsulitis are changes that occur early on and are assumed to be associated with repetitive trauma.^{4,5} This aetiology originates most often from overuse and conformational problems predisposing the horse to inappropriate biomechanical forces on the articular cartilage.⁵

Inflammatory mediators (cytokines, prostaglandin E2, and matrix metalloproteinases) are released by reactive synovial cells in response to cartilage wear products within synovial fluid and occurs in both naturally and experimentally induced OA.^{31, 41, 42, 43, 44} Clinically, synovitis is seen as a palpable joint swelling due to either synovial effusion or thickening of the synovium.^{38, 45} If this persists, fibrosis and increased friction in the joint capsule will develop, resulting in thickening of the joint capsule and loss of the normal range of joint motion.⁴⁶ Therefore rapid resolution of synovitis and capsulitis is critical in the management of OA because synovitis induces cartilage matrix degradation.¹⁶

Normal



Osteoarthritis

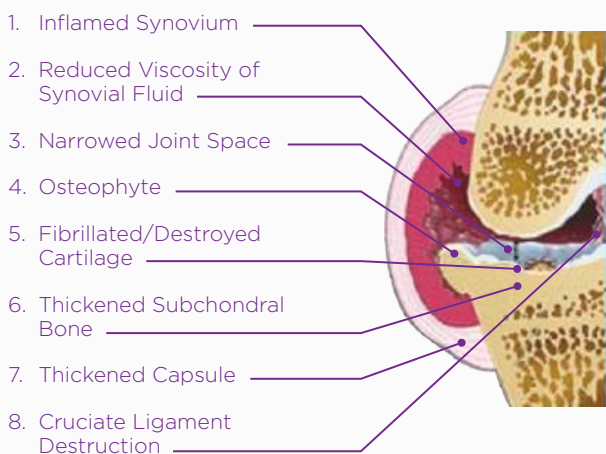


Figure 3. Joint overview: normal vs osteoarthritic lesions

Pain and Synovitis

Two general types of pain stimuli in synovial joints can be distinguished. Mechanical stimuli, generated by (severe) mechanical changes in the environment of the joint (e.g., by direct trauma), and chemical stimuli resulting from tissue inflammation.² The stimuli are detected and forwarded by different types of receptors; mechanoreceptors and nociceptors, to peripheral nerves, spinal cord and ultimately to the brain to be processed, modulated and perceived.

Synovitis, however, is a single important factor that contributes to the pain of OA through joint effusion, swelling and capsulitis that in turn will activate mechanoreceptors in the joint capsule and result in direct chemical stimulation of nociceptors.²

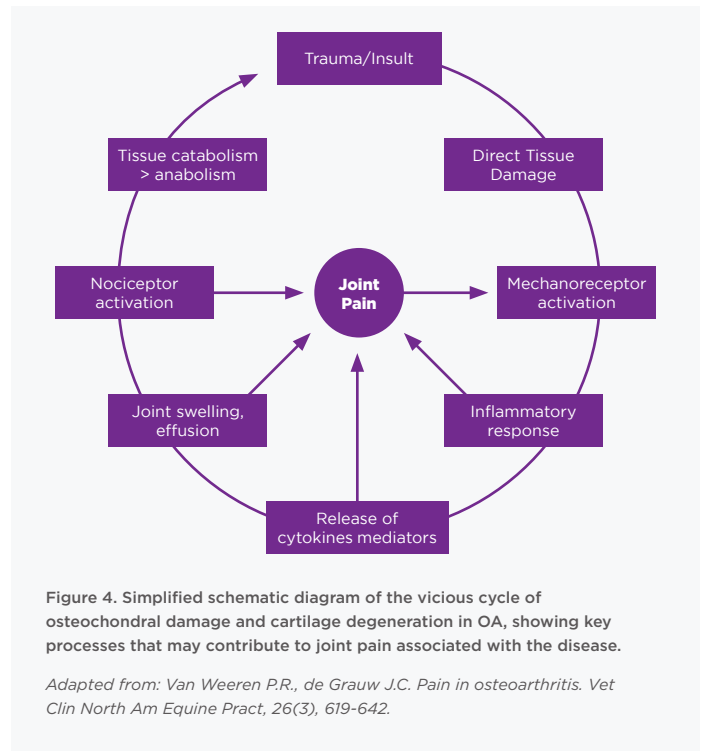
The rapid resolution of lameness attributable to pain is noticeably the principal concern of owners and trainers and the reason why horses present for veterinary care.⁸ There is a weak correlation between the magnitude of pain and the severity of articular damage observed.³¹ Synovitis, however, is a single important factor that contributes to the pain of OA through joint effusion, swelling and capsulitis that in turn will activate mechanoreceptors in the joint capsule and result in direct chemical stimulation of nociceptors.²

In articular tissues, four types of afferent receptors are found;

- Type 1 (low-threshold mechanoreceptors with proprioceptive function, located in the joint capsule)
- Type 2 (low-threshold mechanoreceptors activated during motion with dynamic proprioceptive function and located at the joint capsule/sub-synovial tissue junction)
- Type 3 (high threshold mechanoreceptors and nociceptors, activated during physiologic limits and located near bony insertions of IA and peri-articular ligaments) and;
- Type 4 (polymodal high threshold nociceptors found as free nerve endings responding to thermal, chemical and mechanical stimuli, located in the synovial membrane).²

Nociception will in most cases be stimulated or enhanced by inflammation. In addition to mechanoreceptors stimulated by mechanical influences, they can become hypersensitized by chemical stimuli released during the inflammatory process.² Furthermore, mechanical stimulation itself may, through tissue damage, elicit an inflammatory response with the release of pro-nociceptive mediators.

Such as the OA cascade ensues within the joint tissues, pain results attributable to synovitis and capsulitis as well as subchondral bone exposure, remodeling or bone marrow oedema and marginal periosteal activation associated with osteophytosis.⁴⁷



ArthramidVet® 2.5% PAAG

CHEMISTRY AND MANUFACTURING

Chemistry

ArthramidVet® 2.5% Polyacrylamide hydrogel (2.5% PAAG) is an inert, non-pyrogenic and neuro-innocuous polymer gel consisting of 97.5% sterile water and 2.5% cross-linked polyacrylamide with water exchanging capabilities. (Contura International A/S, Soborg, Denmark). Its biocompatibility in soft tissues has been demonstrated and histopathological studies of subcutaneous tissues from mice, rats, rabbits, pigs, horses and humans have shown it supports cell growth and tissue integration and possesses a permanent, stable augmentation effect due to constant molecular water exchange with its host tissue.^{9, 48, 49, 50}

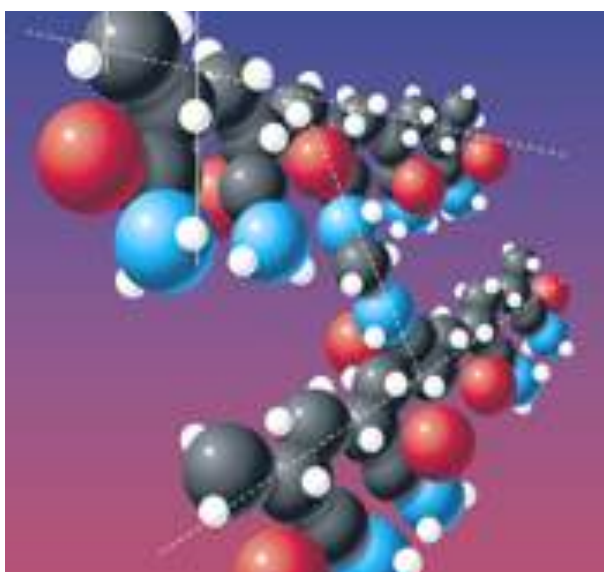


Figure 5. 3D molecular representation of 2.5% PAAG showing cross linking between two molecules of polyacrylamide.

Shown it supports cell growth and tissue integration and possesses a permanent, stable augmentation effect in host tissue.

2.5% PAAG is a gel similar to hyaluronic acid in overall structure and tissue compatibility,³³ but with a longer lasting viscous effect, as it is non-degradable. 2.5% PAAG has been used in human medicine for more than 16 years for the

augmentation of connective tissues such as skin and bladder neck.⁵¹ The current direction of hydrogel research is focusing on their use as bioactive materials to regulate stem cell fate, drug delivery, and now for the management of OA in both animals and humans.^{52, 53}




Figure 6. Representative image of 2.5% PAAG using scanning electron microscopy. Scale Bar = 1.0 Qm showing porosity of the gel structure.

Manufacturing

ArthramidVet® (AV) is produced by a patented technology called In-line Cross-Linking Technology (ILX Technology), forcing water molecules between the cross-linked polymers of polyacrylamide (CAS No. 9003-05-8), that provides the gel with exceptional molecular stability and the ability to retain its viscoelastic properties in situ. AV is hydrophilic, due to its chemical structure, and has an irreversible and steady-state backbone, with lightly bound water molecules that can interchange with water molecules of surrounding tissue.

Patented technology called In-line Cross-Linking Technology (ILX Technology) giving exceptional molecular stability and, the ability to retain its viscoelastic properties in situ

ArthramidVet® 2.5% PAAG

HISTORY OF ITS USE IN CLINICAL STUDIES

Clinical Efficacy

Results in animals and humans show long-lasting positive effects on the symptoms of OA after treatment with 2.5% PAAG.⁹ Two papers published in 2012, were the first to report prospective clinical trials on the efficacy of 2.5% PAAG in horses. Tnibar et al. (2012) evaluated 33 horses older than two years with confirmed OA in only one joint based on clinical evaluation, intra-articular anaesthesia and imaging (radiography, magnetic resonance imaging (MRI) or arthroscopy) and followed up at 1, 3 and 6 months after treatment with 2mls of 2.5% PAAG.⁵⁴ At six months 70% (23/33) of the horses were lame-free concluding 2.5% PAAG is an effective and safe treatment for symptomatic OA in horses and warranted further studies.

Janssen et al. (2012) likewise demonstrated that 1ml of 2.5% PAAG injected into the forelimb distal interphalangeal joint of 12 horses (with 12 treated joints) used for advanced showjumping, with MRI confirmed OA, resulted in 67% of individuals becoming lame free for up to 6 months, with 16.7% improving at least 1 lameness grade and 16.7% showing no signs of improvement.⁵⁵ All horses were previously poorly responsive to triamcinolone acetonide (TA) +/- ACS.

Tnibar et al. (2014) subsequently conducted a controlled pilot study on the use of 2.5% PAAG in surgically created OA affected stifle joints in six goats.^{32, 51} The left stifle joint had the medial collateral ligament transected, the medial meniscus bisected at its midpoint, and a partial thickness cartilage lesion created on the medial femoral-tibial plateau. All goats were allowed free exercise at pasture for the duration of the study, lasting seven months. Three months after surgery, four goats had 2mls of 2.5% PAAG administered into the medial femorotibial joint, and two had 2mls of 0.9% sodium chloride injected, to serve as a control. All goats were observed by ground and treadmill videography at 0, 1, 3, 4, 5 and 7 months, for three blinded observers to assess. At seven months, 3 of 4 AV treated goats were free from lameness, and both within the control group were lame. MRI was conducted on all goats at 0, 3, 4, 5 and 7 months demonstrating a reduction

and then stabilisation of OA lesions in the 3 lame free goats in the AV treated group and slight deterioration in 1 lame goat in the AV treated group, with both goats in the control group showing marked deterioration of OA lesions.

Tnibar et al. (2014) also compared the efficacy of 2mls of 2.5% PAAG with 12mg of triamcinolone acetonide (TA) and 20mg of hyaluronic acid (HA), when injected into a metacarpal/metatarsophalangeal (fetlock) joint, in 40 Warmblood horses used for dressage, showjumping or eventing.^{10, 20} Horses were assigned into 1 of 2 treatment groups after clinical examination, intra-articular anaesthesia, radiological and MRI assessment, and were clinically evaluated at 1, 3 and 6-months post-treatment. The proportion of lame-free horses were 55%, 65%, and 75% respectively in the 2.5% PAAG treated group and 15%, 40%, and 35% in the control (TA-HA) group. The study concluded that horses treated with 2.5% PAAG were significantly less lame ($p < 0.001$) than those receiving positive control treatment (TA-HA). Tnibar et al. (2015) expanded further, assessing the efficacy of 2.5% PAAG in the management of OA in a single joint of 43 horses over 24 months.^{33, 35} Horses had been lame for 1-6 months before treatment, with the remainder being lame for longer than six months and 37 had previously received other anti-arthritis medication. The proportion of lame free horses at 1, 3, 6, 12 and 24 months was 60%, 67%, 79%, 81% and 82.5% respectively.

Bathe et al. (2016) assessed the efficacy of 2.5% PAAG in 18 forelimb distal and proximal interphalangeal joints of sports horses that were previously treated and unresponsive to corticosteroids.⁵⁶ All horses had a diagnosis of OA based on clinical evaluation, diagnostic analgesia, radiology, and MRI, with the average duration of lameness being 15 months.

Horses were treated with 1ml of 2.5% PAAG and rested from exercise for four weeks, before a gradual return to full exercise. Follow up data showed that at 12 months' post-treatment, 12 (67.7%) returned to full exercise, 3 (16.7%) returned to exercise but at a lower level of intensity and 3 (16.7%) failed to improve.

De Clifford and Lowe et al. (2019) investigated the efficacy of 2.5% PAAG in the treatment of carpal and metacarpophalangeal joint lameness in flat-racing Thoroughbreds at a single training facility.¹¹ 49 horses with a total of 89 affected joints satisfied the inclusion and exclusion criteria based on clinical presentation, intra-articular analgesia, and radiological assessment.

The percentage of horses lame-free following a single intra-articular injection of 2ml of 2.5% PAAG was 65% (p<0.001) at twenty-four weeks, with a further 14% improving to at least some degree and enough to remain in race training. These results again showed that 2.5% PAAG (ArthramidVet®) is safe and effective at alleviating the clinical signs of OA.

Recently, an observational pilot study of 118 human knee cases with OA treated with 2.5% PAAG, also showed significant improvement (p<0.0001) of OA symptoms, even after 12 months.⁵⁷

Prospective Double-Blinded Positive Control Study

Lowe and de Clifford, et al, 2021 (JEVS; 103780), conducted a prospective double-blinded positive-control study to investigate the efficacy of a 2.5% polyacrylamide hydrogel in the management of inter-carpal joint lameness in Thoroughbreds.

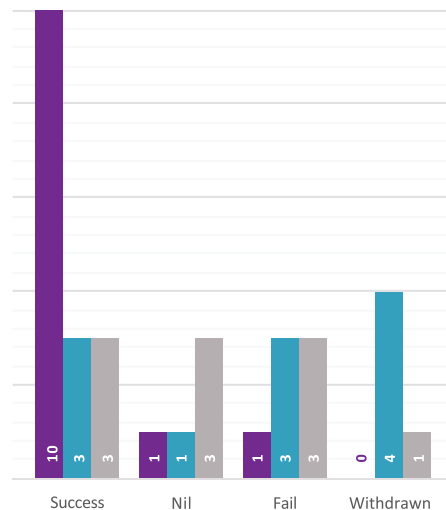
Thirty-three flat-racing Thoroughbreds in full training at a single training facility with lameness (AAEP 1-3/5) localised to the inter-carpal joint by intra-articular anaesthesia and radiological assessment were enrolled. Horses were randomly allocated to be treated intra-articularly with either 2mls of 2.5% PAAG, 12mg of triamcinolone acetonide or 20mg of sodium hyaluronate (followed by two further intravenous treatments of 40mg, at weekly intervals), by a treating veterinarian blinded to the examinations at enrolment. All horses were rested for 48 hours' post-treatment before re-entering an unaltered training regime.

Compared to the horses that received triamcinolone acetonide or sodium hyaluronate, horses treated with 2.5% PAAG showed a higher probability of resolution of lameness, joint effusion and reaction to flexion at 4 (P<0.05) and 6 (p<0.05) weeks, with no difference seen between groups at two weeks. There was no significant difference between the triamcinolone acetonide and sodium

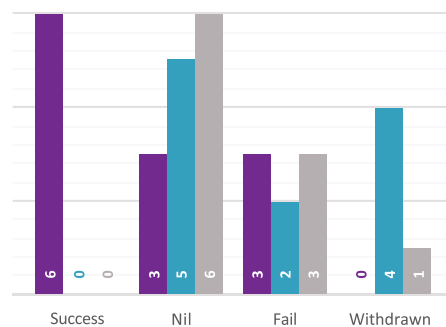
hyaluronate groups at any time point. 8/12 (67%) of horses treated with the 2.5% polyacrylamide hydrogel were lame free at 12 weeks.

This report concluded that 2.5% PAAG could be used in the management of joint lameness in racing Thoroughbreds and is superior to and longer lasting than both Triamcinolone and Hyaluronic Acid.

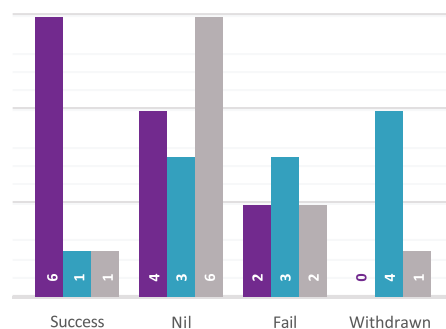
LAMENESS OUTCOME BY TREATMENT AT 6 WEEKS



JOINT EFFUSION OUTCOME BY TREATMENT AT 6 WEEKS



REACTION TO FLEXION OUTCOME BY TREATMENT AT 6 WEEKS



■ 2.5% PAAG ■ TA ■ HA

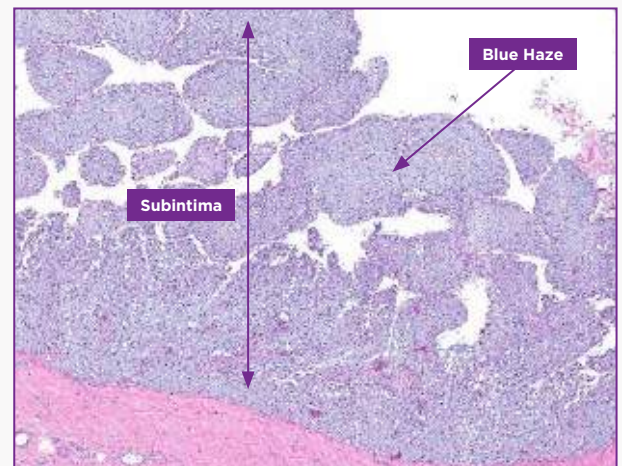
Histological Studies

Christensen et al. (2016) present a thorough histological review of the synovial incorporation of 2.5% PAAG after injection into normal and OA animal joints.⁹ Vessel in-growth begins immediately after gel injection with host macrophages entering the gel, which is unable to engulf the polymer. These are gradually replaced by fibroblasts and endothelial cells, which in time develop into a thin vessel-bearing fibrous network inside the gel. Integration and invasion of synovial cells in the gel is seen by day 14 with a sub-synovial layer traversed by thin strands of connective tissue and vessels covered by a synovial lining facing the joint cavity formed by day 30 and at up to 2 years post injection.⁹

De Clifford and Lowe (unpublished) have demonstrated similar histological findings. The 2.5% PAAG appears as a blue granular material gel in the subintima, when injected into normal and OA equine synovial joints. The local response comprised of macrophages and surface synoviocytes (type A cells) that were attempting to phagocytose the hydrogel at day 14 and 42 post-treatment. There is evidence of binucleate and multinucleate macrophages indicating a response to a persistent stimulus. Also noted was an increase in fibroblasts and collagenous tissue surrounding blood vessels, together with visible hyperplasia and hypertrophy of the synoviocyte layers of the intima. This noticeable rejuvenation of the synovium may improve the nature of the synovial fluid. There were no significant amounts of gel material overlying the synovial surface.

This study also demonstrated no evidence of neutrophilic inflammation, fibrin deposition, mineralisation, or cell death, or other inflammatory cell types. This implies a low level of irritation and antigenicity. Indeed, studies on 2.5% PAAG have not found the polymer to act as a nidus or foreign body with any potential to harbour bacterial infection,^{11,33} and is unlikely to be detrimental to managing joint sepsis or surgical intervention in the future.

3 y.o. TB filly; 14 days; LFC Prox



5 y.o. TB gelding; 42 days; LFC Prox

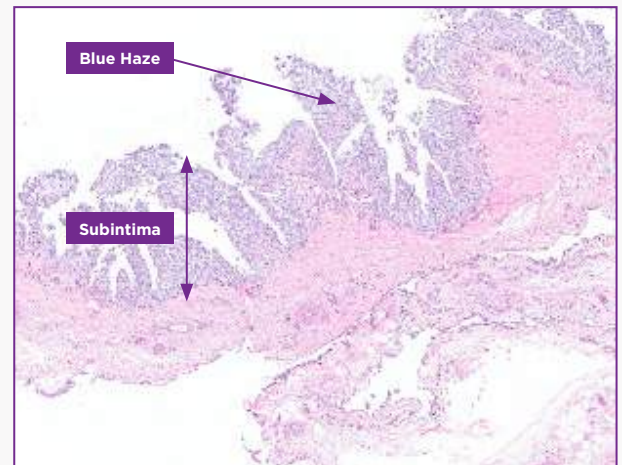


Figure 8. Histological sections of the subintima layer of the synovial membrane. 2.5% PAAG can be seen as a 'blue haze' integrated into the subintima, 14 days and 42 days after treatment. Images captured at 4x magnification.

5 y.o. TB gelding; 42 days; RFC Prox

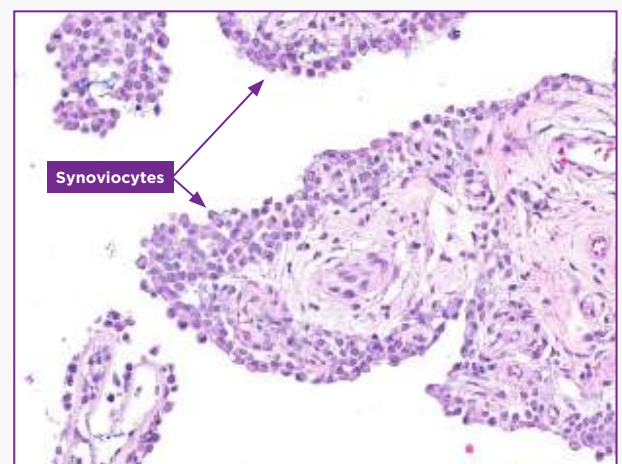


Figure 9. Histological section of the intima layer of the synovial membrane. Synoviocytes are larger than normal (hypertrophy) and present in greater numbers (hyperplasia) in response to 2.5% PAAG 42 days after treatment. Images captured at 20x magnification.

ArthramidVet® 2.5% PAAG

MECHANISM OF ACTION

Introduction

Arthritis describes inflammation of a joint and occurs after single or repetitive episodes of trauma.³⁴ As previously described, the term incorporates synovitis, capsulitis, sprain, intra-articular fractures, meniscal tears, and OA. These pathological conditions are 'a group of overlapping distinct diseases which may have different aetiologies, but with similar biologic, morphologic, and clinical outcomes'. Although conventional concepts of OA emphasize the direct and predominant involvement of cartilage and bone in OA development, it is increasingly recognised that the synovium has a significant effect on the central pathophysiological event of cartilage matrix depletion.⁵¹



2.5% PAAG - A Novel Treatment

2.5% PAAG is a novel treatment for OA, and its clinical efficacy recorded in horses,^{10, 11, 33, 55}, goat and human models.^{32, 51, 57} 2.5% PAAG is different from other described hydrogels which have different concentrations of polyacrylamide and may contain other components as well e.g. silver ions.

Furthermore, PAAG products, although often considered equal, have clear differences in composition, manufacturing and injection techniques as well as their ability to interact with surrounding tissues. Characteristics that ultimately determine the safety and effectiveness of each hydrogel.⁵⁸

PAAG products, although often considered equal, have clear differences in composition, manufacturing and injection techniques as well as their ability to interact with surrounding tissues. Characteristics that ultimately determine the safety and effectiveness of each hydrogel.⁵⁸

Hydrogels are 3-dimensional, hydrophilic, polymeric networks capable of absorbing large amounts of water or biological fluids.⁵⁹ Due to their high-water content, porosity and soft consistency, they closely simulate natural living tissue. In addition to biocompatibility, 2.5% PAAG is shown to be long-lasting and non-degradable.^{11, 49, 51} Histological examinations of treated OA joints, while showing a large number of infiltrating macrophages with some evidence of phagocytosis, illustrate the 2.5% PAAG is fully integrated into the synovial membrane by between 14 to 42 days post-treatment,¹¹ and still present at 2 years.⁹ By comparison, clinical trials investigating the use of a 4% PAAG, highlight those differences in composition, metabolism, and mechanism of action. i.e. 4% PAAG is degradable, mechanically removed by phagocytosing

synoviocytes over time and positive outcomes are believed to result from direct lubrication and protection, acting as a boundary lubricant.⁶⁰

Mechanism of Action 2.5% PAAG

Tnibar et al. (2015) investigated possible biomechanical mechanisms of action of 2.5% PAAG in OA joints, based on MRI, pathology and joint capsule elasticity investigations.³³ Stabilization of OA lesions was seen on MRI indicating a possible protective effect of the 2.5% PAAG attributable to the high visco-supplementation. Additionally, an increase in joint capsule elasticity, caused by augmentation of the soft tissues of the joint and in particular, the synovial membrane, may reduce the overall joint capsule stiffness. 2.5% PAAG significantly alleviated lameness during the first month after treatment and lasted and increased progressively until six months, with stabilization between 6 and 24 months. Success was attributed to improved load transfer capacity of the joint capsule, which in turn reduces mechanoreceptor activation and disrupting the catabolic pathways characteristic of OA.

2.5% PAAG has a disease-modifying effect from its incorporation and augmentation of the synovial membrane and high visco-supplementation properties³²

These findings are supported in clinical trials in horses, where OA joints that respond to treatment of 2.5% PAAG show a greater chance of resolution of lameness, joint effusion, and reaction to flexion at four and six weeks.¹¹ The dramatic and significant reduction in joint effusion supports the suggestion that 2.5% PAAG has a disease-modifying effect from its incorporation and augmentation of the synovial membrane and high visco-supplementation properties.³² The 24 month follow up trial also demonstrated that joint effusion scores decreased significantly over time.³³

Joints effected by OA typically show joint stiffness, which is a significant source of pain.⁵¹ A recent study on knee joint stiffness in humans supports this concept, showing that the stiffness coefficient was higher in individuals with painful OA.⁶¹ By augmenting with the synovial membrane, which subsequently decreases joint capsule and joint stiffness, the 2.5% PAAG

may relieve the pain associated with the OA joint.⁵¹ Indeed experimental studies and clinical trials demonstrate a significant reduction in pain on joint flexion tests in horses diagnosed with OA and treated with 2.5% PAAG.^{10, 11, 33}

An increase in joint capsule elasticity, caused by augmentation of the soft tissues of the joint and in particular, the synovial membrane, may reduce the overall joint capsule stiffness

Time after administration of ArthramidVet®

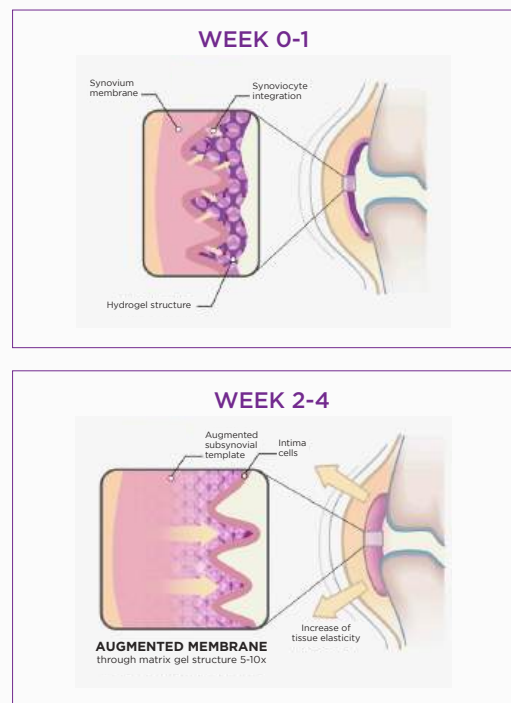


Fig. 10: Mechanism of action of 2.5% PAAG. A. Integration of AV into the connective tissue of the synovial joint capsule at Week 0-1 after treatment with 2.5% PAAG. By week 2-4, 2.5% PAAG increases thickness of synovial membrane, improving tissue elasticity.

Conclusion

Upon injection into the joints the 2.5% PAAG adheres to the synovial lining through its ability to exchange water molecules. This will reduce exposure of synoviocytes to pro-inflammatory cytokines in the inflamed or diseased joint.

The infiltration of mononuclear cells observed in synoviocentesis may further lead to the release of anti-inflammatory cytokines (such as IL-1 receptor antagonist protein, transforming growth factor - beta 1, and insulin-like growth factor) among others.

Throughout 14 up to 42 days the gel then becomes fully integrated into the synovial lining and its immediate surrounding tissue of the inner capsule by a combination of cell migration and vessel ingrowth forming a thick, cushion-like membrane consisting of vessel integrated gel covered by a new and hypercellular synovial cell lining. (Refer to previous figures 8 and 9)

The gel then becomes fully integrated into the synovial lining and its immediate surrounding tissue of the inner capsule by a combination of cell migration and vessel ingrowth forming a thick, cushion-like membrane consisting of vessel integrated gel covered by a new and hypercellular synovial cell lining.

As a result, 2.5% PAAG has a long-lasting augmentation effect on both the joint capsule and synovium. It increases the elasticity and tensile strength of the capsule improving its capacity to transfer load (Fig 12).

It is understood that this augmentation and cushioning causes a reduction in mechanoreceptor and nociceptor activation in the capsule itself.

The formation of a new and hypercellular synovial cell lining further improves the nature of synovial fluid within the joint itself and, combined these properties reduce the pain and inflammation of synovitis and restore the joint to healthier function.





Fig. 11. Scanning electron microscopy images from treated joints 49 days post injection with 2.5% PAAG. After integration of 2.5% PAAG into the subintima, thin strands of collagen deposition can be visualised. Scale bar = 1.0 μ m.

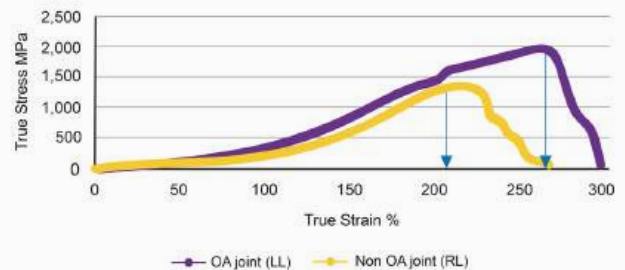


Fig. 12. Comparison of joint capsule elasticity of an osteoarthritic knee (purple) vs. non osteoarthritic knee (yellow) in one of the 2.5% PAAG treated goats.³² Tnibar 2014

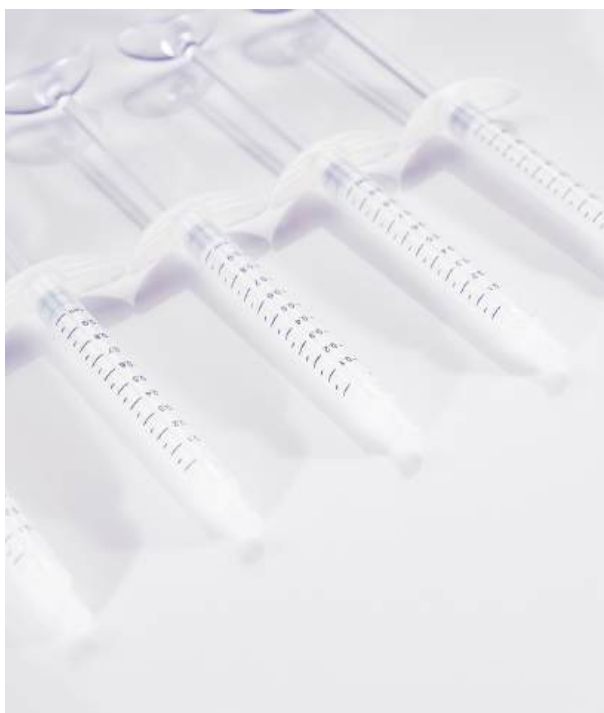ArthramidVet® 2.5% PAAG

CLINICAL SAFETY

Safety Studies

Both in vitro and in vivo studies have taken place, designed to generate data on the safety of AV and to support regulatory submissions for market authorisation. Current OA treatments are focused on reducing symptoms and there are few effective treatments.⁹ In addition, some treatments have been associated with significant toxicities and contra-indications, and their use restricted across populations.^{9, 62} Multiple studies have shown 2.5% PAAG is safe for use in animals and humans.^{9, 10, 11, 32, 33, 51, 55, 57}

Multiple studies have shown 2.5% PAAG is safe for use in animals and humans.



In Vitro

Any potential cytotoxic effects of ArthramidVet® have been independently analysed using cell growth analysis via BCA-Staining. The methodology employed in this manner of cytotoxicity testing represents one of the easiest

methods for the analysis of detrimental effects of substances, and cell culture techniques allow rapid yet sensitive diagnosis of the biological reactivity of diffusible components of materials.^{63, 64} The BCA-Staining test predicts cytotoxic or necrotic effects of medical devices or materials with good correlation to animal experiments and high sensitivity.^{65, 66} Under this testing model no cytotoxic substances are released from 2.5% PAAG.

Monomers of acrylamides are known to be neurotoxic to animals and humans whereas polyacrylamides are non-toxic.

The active substance used to manufacture 2.5% PAAG is the same as the finished product i.e. cross-linked polyacrylamide hydrogel (CAS No. 9003-05-8). The product is known to be exceptionally stable and extensive washing occurs during the manufacturing process to remove any potential contaminants.

Monomers of acrylamides are known to be neurotoxic to animals and humans whereas polyacrylamides are non-toxic.⁵⁸ Any possible toxic effects of residual monomers from manufacturing have been calculated using recommendations from the United States Environmental Protection Agency (2007).⁶⁷ Levels do not raise biological safety concerns, either in data-derived or worst-case scenarios. The European Medical Agency (EMA) likewise recently ruled that 2.5% PAAG is considered as not falling within the scope of regulation with regard to residues for veterinary medicinal products.⁶⁸

Acrylamide in toxic levels would also be capable of producing an axonopathy by transection of neurons – that portion of the axon which is separated anatomically from the nerve cell body and the myelin surrounding the axon degenerates.⁶⁹ Thibar. et al. (2017) assessed the presence of nerves in the synovial membrane in response to 2.5% PAAG treatment.⁵¹ In treatment groups, nerves were seen in similar patterns as those in control groups; nerves were intact with normal morphology and in normal numbers, further highlighting no neurotoxic effects.

In Vivo

In vivo, studies have investigated the safety of ArthramidVet® at 1x, 2x, and 5x the standard recommended dose, against controls (de Clifford, Lowe and Sommerville, pending publication). Follow up examinations were performed at Days 1, 3, 7, and 14 after treatment. The safety of the product was evaluated using physical examination, including joint health and mobility, and evaluation of complete blood hematology, serum biochemistry and acute phase proteins (SAA). While results showed some mild variations between individuals and groups, they were unrelated to timing of treatment and consistent with normal variations due to breed, exercise, diet, climate, and history, and not the treatment itself. The study was conducted following VICH GL43 guidelines and demonstrates that the intraarticular treatment of equines with 2.5% PAAG is safe and with no adverse reactions or detrimental clinical effects in any treatment group, even at up to 5x the recommended dose. These findings align with numerous published clinical studies where no adverse reactions using 2.5% PAAG have been recorded.^{9, 10, 32, 33, 51, 55}

Studies demonstrate that the intraarticular treatment of equines with 2.5% PAAG is safe and with no adverse reactions or detrimental clinical effects in any treatment group, even at up to 5x the recommended dose

Synoviocentesis Studies

Further reports (pending publication) have serially analysed synoviocentesis samples to investigate synovial fluid composition and biomarkers in both healthy and OA horses, pre and post injection, with 2.5% PAAG. The first study performed serial synovial fluid analysis at Day 0 (baseline), and Days 7, 14, 28 and 42 post injection with 2mls 2.5% PAAG injected into the intercarpal joint of 3 healthy horses. The contralateral carpus was used as a control. Independent analysis of the synoviocentesis samples showed all results stayed within normal limits at all times and matched controls at 42 days.

A second study similarly analysed pre and post-treatment synoviocentesis samples from a total of ten healthy horses at up to 90 days after treatment. In this case, pre-treatment samples

from the same joint were used as controls. In general although horses showed mild elevations in total nucleated cell counts around Day 14, mostly mononuclear cells (macrophages) and lymphocytes, these differences were less apparent by Day 42. Again, all levels remained within normal laboratory limits at all times.

Independent analysis of the synoviocentesis samples showed all results stayed within normal limits at all times and matched controls at 42 days. There were no elevations in any of the pro-inflammatory cytokines in any treatment group at any time.

Thirdly, ten matched synovial fluid samples were collected from mature horses with clinical evidence of OA. In this case the horses had been treated with one of either 2.5% PAAG, Triamcinolone acetate (TA), or Hyaluronic Acid (HA) at Day 0. Synovial samples were collected pre-treatment and at 30 days post treatment. A 23-plex equine assay kit at an independent laboratory, blinded to the treatment groups, measured levels of pro-inflammatory cytokines. There were no elevations in any of the pro-inflammatory cytokines in any treatment group at any time. It was concluded that 2.5% PAAG does not cause any pro-inflammatory reaction in the joint and was non-inferior to currently registered treatments (TA and HA).

Conclusion

2.5% PAAG has had widespread use in human medicine for many years and, together these studies are consistent in their findings, that 2.5% PAAG is safe, non-pyrogenic and neuro-innocuous.

ArthramidVet® 2.5% PAAG

PUTTING IT INTO PRACTICE

Case Selection

Understanding the complexity of disease processes associated with joint pain remains a constant dilemma in clinical practice and, as with any disease process an accurate diagnosis is essential. Arthritis describes inflammation of a joint and can occur after single or repetitive episodes of trauma. The term incorporates synovitis, capsulitis, sprain, intra-articular fractures, meniscal tears and osteoarthritis(OA). Sub-chondral bone injury also plays a role.

Cases suitable for treatment with ArthramidVet® are those in which lameness is localised to the joint by clinical examination, intra-articular analgesia, +/- radiography, ultrasound, MRI, CT and/or Scintigraphy. Conditions that respond to treatment with ArthramidVet® include acute and chronic synovitis, capsulitis, meniscal tears, OA and subchondral bone cysts. It is essential that anamnesis of data of ongoing infection, concomitant medication, surgery or potential fracture is reviewed prior to injection to prevent possible infections or use of the product for conditions other than for which it is indicated.

Initially, ArthramidVet® was used only in chronic OA cases, but it is now recommended for use as early as possible in the disease process, e.g. persistent lameness-causing synovitis and capsular stiffness. There is even further work being done to investigate its use prophylactically to reduce joint lameness and lost days in training.

Case Management

Following treatment animals should be rested for 48 hours. After this time the animal can return to low impact exercise and until a response to treatment is seen-typically 2-4 weeks after treatment.

Clinical studies show that tissue integration and subsequent augmentation of the joint capsule takes between 2 and 4 weeks to occur, although a response to treatment can be seen earlier than that in some cases; it is understood that mononuclear cells producing a myriad of anti-inflammatory compounds in response to the initial exposure to the 2.5%



PAAG temporarily reduce inflammation within the medicated joint, whilst the secondary change in joint capsule elastance occurs.

Animals typically show a gradual reduction in lameness during the first week after treatment and a concurrent reduction in reaction to passive flexion. This continues to improve over the ensuing weeks. By 4 to 6 weeks no further improvement is expected. Re-examination at 4 to 6 weeks is therefore indicated to either administer a second dose - in those that have only partially responded (around 15% of cases) or to reassess accuracy of the diagnosis.

It is important for owners to understand this time lag for a treatment effect to be seen as this contrasts with conventional therapies. In this respect and, due to its long lasting effect, it may also be prudent to consider treating the animal during periods of reduced exercise demands or earlier in the animals training programme that normally considered.

ArthramidVet® can be used concurrently with other medications that assist with subchondral bone pain. It will not directly treat subchondral bone pain, but it may aid joint function by reducing shear forces on the subchondral bone plate. Veterinarian's should also still consider using conventional IA medications when a more immediate reduction in joint inflammation is required, and treatment of ArthramidVet® taking place 2-4 weeks later (depending on the IA medication used) to assist in longer term management of the affected joint(s). Concurrent use of NSAID's with ArthramidVet® may also be useful and carries no contra-indications.

Dosages

The following doses are recommended based on clinical efficacy;

Distal Interphalangeal: 1-2mL

Proximal Interphalangeal: 1 mL

Metacarpo/tarso-phalangeal: 1-3 mL

Carpus: 1-3mL

Tarsometatarsal/ Distal Intertarsal: 1 mL

Tarsocrural: 2-3 mL

Shoulder: 2-3 mL

Stifles: 1-2 mL per compartment

There is evidence that there is a dose-dependent response. These doses may therefore be altered depending on disease severity. (e.g. a mild, moderate or severe case of OA in a metacarpophalangeal joint may be treated with 1, 2, or 3mls of 2.5% PAAG, respectively).

It is necessary to reassess the response to treatment at 4-6 weeks and re-medicate 'partial responders' at this time. Repeated doses can be given at 6 to 12 month intervals if clinically indicated.

Key Points

- For use in joint lameness that responds to IA anaesthesia.
- Cases that have joint effusion and react to flexion appear to respond the best.
- There is no requirement to see radiographic changes of OA to justify early treatment
- Dose can be varied depending on the severity of the disease progression.
- Repeat injections can take place in 'partial-responders' 4-6 weeks after initial treatment.

ArthramidVet® 2.5% PAAG

REFERENCES

1. Goodrich, L.R. and Nixon, A.J., Medical treatment of osteoarthritis in the horse – A review. *Vet J.* 2006; 171: 51-69.
2. van Weeren, P.R. and de Grauw, J.C., Pain in osteoarthritis. *Vet Clin Equine.* 2010; 26: 619-642.
3. National Animal Health Monitoring Systems, Lameness and laminitis in US horses. Fort Collins, CO. USDA, APHIS, Veterinary Services-Centres for Epidemiology in Animal Health. 2000.
4. McIlwraith, C.W., Principles and practices of joint disease treatment. In: Ross, M.W., Dyson, S.J., editors. *Diagnosis and management of lameness in the horse.* 2nd edition. Saunders. Missouri, 2011; 840-852.
5. McIlwraith, C.W., General pathobiology of the joint and response to injury. In: McIlwraith, C.W., Trotter, G.W., editors. *Joint disease in the horse.* Saunders. Philadelphia, 1996; 40-70.
6. Frisbie, D.D., Kawcak, C.E., Werpy, N.M., McIlwraith, C.W., Evaluation of polysulfated glycosaminoglycan or sodium hyaluron administered intra-articularly for treatment of horses with experimentally induced osteoarthritis. *AM J Vet Res.* 2009; 70: 203-209.
7. Frisbie, D.D., McIlwraith, C.W., Kawcak, C.E., Werpy, N.M., Evaluation of intraarticular hyaluron, sodium chondroitin sulfate and N-acetyl-D-glucosamine combination versus saline (0.9% NaCl) for osteoarthritis using an equine model. *Vet J.* 2013; 197: 824-829.
8. Caron, J.P., Intra-articular injections for joint diseases in horses. *Vet Clin North Am Equine Pract.* 2005; 21: 559-573.
9. Christensen, L., Camitz, L., Illigen, K.E., Hansen, M., Sarvaa, R., Conaghan, P.G., Synovial incorporation of polyacrylamide hydrogel after injection into normal and osteoarthritic animal joints. *Osteoarthritis Cartilage.* 2016; 24: 1999-2002.
10. Tnibar, A., Schougaard, H., Koene, M., Christensen, L.H., Markussen, B., A controlled clinical trial on the efficacy of an intra-articular polyacrylamide hydrogel in horses with osteoarthritis. 23rd Annual Scientific Meeting of the European College of Veterinary Surgeons (ECVS), Copenhagen, July 2014.
11. De Clifford, L.T., Lowe, J.N., McKellar, C.D., Chambers, M., David, F., A single site, double-blinded, prospective study on the comparative efficacy of a 2.5% polyacrylamide hydrogel in horses with inter-carpal joint lameness. *Journal Equine Vet Science*; [Online] 2019. https://www.sciencedirect.com/science/article/pii/S0737080618307615?dgcid=rss_sd_all
12. Sandoval, J.A., Lopez, C., Carmona, J.U., Therapies intended for joint regenerations in the horse. *Arch Med Vet.* 2013; 45: 229-236.
13. Bogers, S.H., Cell-based therapies for joint disease in veterinary medicine: What we have learned and what we need to know. *Front Vet Sci.* 2018; 5: 70.
14. Kamm, J.L., Nixon, A.J., Witte, T.H., Cytokine and catabolic enzyme expression in synovium, synovial fluid and articular cartilage of naturally osteoarthritic equine carpi. *Equine Vet J.* 2010; 42(8): 693-699.
15. Whitton, R.C., Jackson, M.A., Campbell, A.J., Anderson, G.A., Parkin, T.D., Morton, J.M., Boden, L.A., Musculoskeletal injury rates in Thoroughbred racehorses following local steroid injection. *Vet J.* 2013; 200(1): 71-76.
16. McIlwraith, C.W., Principles and practices of joint disease treatment. In: Ross, M., Dyson, S., editors. *Diagnosis and management of lameness in the horse.* 2nd edition. Saunders. Missouri, 2011b; 840-852.
17. Canapp Jr, S.O., Leasure, C.S., Cox, C., Ibrahim, V., Carr, B.J., Partial cranial cruciate ligament tears treated with stem cell and platelet-rich plasma combination therapy in 36 dogs: A retrospective study. *Front Vet Sci.* 2016. 3(112).
18. Broeck, S.Y., Seys, B., Suls, M., Vandenberghe, A., Marien, T., Adriaensen, E., Declercq, J., Van Hecke, L., Braun, G., Hellman, K., Spaas, J.H., Equine allogenic chondrogenic induced mesenchymal stem cells are an effective treatment for degenerative joint disease in horses. *Stem Cells Dev.* 2019; 28(6): 410-422.
19. Frisbie, D.D., Kisiday, J.D., Kawcak, C.E., Werpy, M., McIlwraith, C.W., Evaluation of adipose-derived stromal vascular fraction or bone marrow-derived mesenchymal stem cells for treatment of osteoarthritis. *J Orthop Res.* 2009; 27: 1675-1680.

20. Lee, K., Park, N., Jung, H., Rim, Y.A., Nam, Y., Lee, J., Park, S.H., Ju, J.H., Mesenchymal stem cells ameliorate experimental arthritis via expression of interleukin-1 receptor antagonist. *PLoS ONE*. 2018; 13(2). <https://doi.org/10.1371/journal.pone.0193086>
21. Todhunter, R.J., Anatomy and physiology of synovial joints. In: McIlwraith, C.W., Trotter, G.W., editors. *Joint disease in the horse*. Saunders. Philadelphia, 1996; 1-28.
22. McIlwraith, C.W., Diseases of joints, tendons and related structures. In: Stashak, T.S., editor. *Adams' lameness in horses*. 5th edition. Lippincott Williams and Wilkins. Philadelphia, 2002; 457-644.
23. Brandt, K.D., Dieppe, P., Radin, E., Ethiopathogenesis of osteoarthritis. *Med Clin North Am*. 2009; 93: 1-24.
24. Sutton, S., Clutterbuck, A., Harris, P., Gent, T., Freeman, S., Foster, N., Barrett-Jolley, R., Mobasher, A., The contribution of the synovium, synovial derived inflammatory cytokines and neuropeptides to the pathogenesis of osteoarthritis. *Vet J*. 2009; 179: 10-24.
25. McIlwraith, C.W., Joint injuries and disease and osteoarthritis. In: Baxter, G.M., editor. *Adams & Stashak's Lameness in horses*. 6th edition. Wiley-Blackwell. Chichester, 2011a; 1267-1291.
26. McIlwraith, C.W., Frisbie, D.D., Kawcak, C.E., The horse as a model of naturally occurring osteoarthritis. *Bone Joint Res*. 2012; 1(11): 297-309.
27. Bondeson, J., Wainwright, S.D., Lauder, S., Amos, N., Hughes, C.E., The role of synovial macrophages and macrophage-produced cytokines in driving aggrecanases, matrix metalloproteinases, and other destructive and inflammatory responses in osteoarthritis. *Arthritis Res Ther*. 2006; 8:R187: 1-12.
28. Loeser, R.F., Molecular mechanisms of cartilage destruction: mechanics, inflammatory mediators and aging collide. *Arthritis Rheum*. 2006; 54: 1357-1360.
29. McIlwraith, C.W., From arthroscopy to gene therapy—30 years of looking in joints. 51th Annual Convention of the American Association of Equine Practitioners: Proceedings of the American Association of Equine Practitioners, Lexington. 2005; 51: 65-113.
30. Frisbie, D.D., McIlwraith, C.W., de Grauw, J.C., Synovial fluid and serum biomarkers. In: *Joint disease in the horse*. 2nd edition. Elsevier. St Louis, 2016; 10:179-191.
31. Caron, J.P., Osteoarthritis. In: Ross, M.W., Dyson, S.J., editors. *Diagnosis and management of lameness in the horse*. 2nd edition. Saunders. Missouri, 2011; 655-668.
32. Tnibar, A., Persson, A., Jensen, H.E., Svalastoga, E., Westrup, U., McEvoy, F., Evaluation of a polyacrylamide hydrogel in the treatment of induced osteoarthritis in a goat model: A pilot randomized controlled Study [abstract]. *Osteoarthritis Cartilage*. 2014; 22: 477.
33. Tnibar, A., Schougaard, H., Camitz, L., Rasmussen, J., Koene, M., Jahn, W., Markussen, B., An international multi-centre prospective study on the efficacy of an intrarticular polyacrylamide hydrogel in horses with osteoarthritis: a 24 month follow up. *Acta Vet Scand*. 2015; 57: 20-27.
34. McIlwraith, C.W., Traumatic arthritis and posttraumatic arthritis in the horse. In: McIlwraith, C.W., Kawcak, C.E., van Weeren, P., editors. *Joint disease in the horse*. 2nd edition. Elsevier. St Louis, 2016; 2: 33-48.
35. Radin, E.L., Burr, D.B., Caterson, B., Mechanical determinants of osteoarthritis. *Semin Arthritis Rheum*. 1991; 21: 12-21.
36. Kapoor, M., Martel-Pelletier, J., Lajeunesse, D., Pelletier, J.P., Fahmi, H., Role of proinflammatory cytokines in the pathophysiology of osteoarthritis. *Nat Rev Rheumatol*. 2011; 7: 33-42.
37. Loeser, R.F., Goldring, S.R., Scanzello, C.R., Goldring, M.B., Osteoarthritis: a disease of the joint as an organ. *Arthritis Rheum*. 2012; 64: 1697-1707.
38. Sellam, J., Berenbaum, F., The role of synovitis in pathophysiology and clinical symptoms of osteoarthritis. *Nat Rev Rheumatol*. 2010; 6: 625-635.
39. Scanzello, C.R. and Goldring, S.R., The role of synovitis in osteoarthritis pathogenesis. *Bone*. 2012; 51(2): 249-257.
40. Radin, E.L. and Paul, I.L., Does cartilage compliance reduce skeletal impact loads? The relative force-attenuating properties of articular cartilage, synovial fluid, periarticular soft tissue and bone. *Arthritis Rheum*. 1970; 13: 139-144.
41. Mow, V.C., Ratcliffe, A., Poole, A.R., Cartilage and diarthrodial joints as paradigms for hierarchical materials and structures. *Bio-materials*. 1992; 13: 67-97.
42. Evans, C.H., Mears, D.C., Stanitski, C.L., Ferrographic analysis of wear in human joints: Evaluation by comparison with arthroscopic examination of symptomatic knee joints. *J Bone Joint Surg*. 1982; 64B: 572-578.

43. Morris, E.A., McDonald, B.S., Webb, A.C., Rosenwasser, L.J., Identification of interleukin-1 in equine osteoarthritis joint effusions. *Am J Vet Res.* 1990; 51: 59-64.
44. Gibson, K.T., Hodge, H., Whittem, T., Inflammatory mediators in equine synovial fluid. *Aust Vet J.* 1996; 73: 148-151.
45. Berenbaum, F., Osteoarthritis as an inflammatory disease (osteoarthritis is not osteoarthrosis!). *Osteoarthritis Cartilage.* 2013; 21: 16-21.
46. Pool, R.R., Pathologic manifestations of joint disease in the athletic horse. In: McIlwraith, C.W., Trotter, G.W., editors. *Joint disease in the horse.* Saunders. Philadelphia, 1996; 87-104.
47. Caron, J.P., Neurogenic factors in joint pain and disease pathogenesis. In: McIlwraith, C.W., Trotter, G.W., editors. *Joint disease in the horse.* WB Saunders. Philadelphia, 1996; 71-80.
48. Christensen, L.H., Nielsen, J.B., Mouritsen, L., Sorensen, M., Lose, G., Tissue integration of polyacrylamide hydrogel: An experimental study of periurethral, perivascular, and mammary gland tissue in the pig. *Dermatol Surg.* 2008; 34: 68-77.
49. Christensen, L.H., Breiting, V.B., Aasted, A., Jorgensen, A., Kebuladze, I., Long-term effects of polyacrylamide hydrogel on human breast tissue. *Plast Reconstr Surg.* 2003; 111(6): 1883-1889.
50. Zarini, E., Supino, R., Pratesi, G., Laccabue, D., Tortoreto, M., Scanziani, E., Ghisleni, G., Paltrinieri, S., et al. Biocompatibility and tissue interactions of a new filler material for medical use. *Plast Reconstr Surg.* 2004; 114: 934-942.
51. Tnibar, A., Persson, A.B., Jensen, H.E., Mechanisms of action of an intraarticular 2.5% polyacrylamide hydrogel (ArthramidVet®) in a goat model of osteoarthritis: Preliminary Observations. *SM J Biomed Eng.* 2017; 3: 1022.
52. Tsou, Y.-H., Khoneisser, J., Huang, P.-C., Xu, X., Hydrogel as a bioactive material to regulate stem cell fate. *Bioactive Materials.* 2016; 1-17.
53. Hoare, T.R. and Kohane, D.S., Hydrogels in drug delivery: progress and challenges. *Polymer* 49. 2008; 1993-2007.
54. Tnibar, A., Schougaard, H., Camitz, L., Rasmussen, J., Koene, M., Jahn, W., Markussen, B., Efficacy of a polyacrylamide hydrogel in horses with symptomatic osteoarthritis: an international multi-centre prospective study. *Equine V J.* 2012; 44: 16.
55. Janssen, I., Koene, M., Lischer, C., Intra-articular use of a polyacrylamide hydrogel as a treatment for osteoarthritis in the distal interphalangeal joint: a case series of 12 horses. *Pferdeheilkunde.* 2012; 28: 650-656.
56. Bathe, A.P., Read, R., Briggs, C., Intra-articular polyacrylamide hydrogel for the treatment of 20 horses with non-responsive osteoarthritis of the interphalangeal joints: a prospective study [abstract]. *Veterinary Orthopaedic Society 43rd Annual Conference, USA.* 2016; 4-5.
57. Henriksen, M., Overgaard, A., Bliddal, H., Initial estimates of efficacy of intra-articular 2.5% polyacrylamide hydrogel for the treatment of knee osteoarthritis: An observational proof-of-concept study [abstract]. *Arthritis Rheumatol.* 2017; 69 (suppl 10).
58. Narins, R.S. and Schmidt, R., Polyacrylamide hydrogel differences: Getting rid of the confusion. *J Drugs Dermatol.* 2011; 10(12): 1370-1375.
59. Calo, E. and Khutoryanskiy, V.V., Biomedical applications of hydrogels: A review of patents and commercial products. *Eur Polym J.* 2015; 65: 252-267.
60. McClure, S.R. and Wang, C., A preliminary field evaluating the efficacy of 4% polyacrylamide hydrogel in horses with osteoarthritis. *J Equine Vet Sci.* 2017; 54: 98-102.
61. Hall, M.C., Doherty, S., Zhang, W., Doherty, M., Knee stiffness and its relationship to severity of radiographic osteoarthritis, pain and self-reported stiffness. *Osteoarthritis Cartilage.* 2014; 22: 92.
62. Kynch, H., Vidal, M., Chouicha, N., Mitchell, M., Kass, P., Cytokine, catabolic enzyme and structural matrix gene expression in synovial fluid following intra-articular administration of triamcinolone acetonide in exercised horses. *Equine Vet J.* 2017; 49: 107-115.
63. Guess, W.L., Autian, J., Toxicity evaluation of Lexan, Kyonar, Rilsan, short-term studies. *J Oral Ther Pharmacol.* 1966; 3(2): 116-123.
64. Stark, D.M., Shopsis, C., Borenfreund, E., Babich, H., Progress and problems in evaluating and validating alternative assays in toxicology. *Fd Chem Toxic.* 1986; 24: 449-455.
65. Autian, J., Dillingham, E.O., Overview of general toxicity testing with emphasis on special tissue culture tests. In: Berky, J., Seherrod, C., editors. *In vitro toxicity testing.* The Franklin University Press. Philadelphia, 1978; 21-49.
66. Wilsnack, R.E., Quantitative cell culture biocompatibility testing of medical devices to animal tests. *Bio-materials.* 1976; 4: 235-261.

67. United States Environmental Protection Agency, 2007. IRIS Toxicological Review of Acrylamide. [Online] Available at: http://ofmpub.epa.gov/eims/eimscomm.getfile?p_download_id=495149 [Accessed 2017].
68. European Medical Agency. 2019. Substances considered as not falling within the scope of Regulation (EC) No. 470/20091, with regard to residues of veterinary medicinal products in foodstuffs of animal origin Available at; https://www.ema.europa.eu/documents/regulatory-procedural-guideline/substances-considered-not-falling-within-scope-regulation-ec-no-470/20091-regard-residues-veterinary-medicinal-products-foodstuffs-animal-origin_.pdf
69. Smith, E. and Oehme, F., Acrylamide and Polyacrylamide: A Review of Production, Use, Environmental Fate and Neurotoxicity. *Comparative Toxicology Laboratories*. 1991; 9(4): 215-219.
70. Ehrle, A., Furst, A., Lischer, C., Efficacy and adverse effects of joint medication in the horse – A review of the literature – Part 2: Regenerative and innovative joint medication in the horse. *Pferdeheilkunde*. 2013; 29: 212-218.
71. Ankorina-Stark, I. and Koene, M., Novel treatment of symptomatic osteoarthritis (OA) in horses [abstract]. *European Veterinary Conference Voorjaarsdagen*. 2011; 273.